

Lens epithelial changes and mutated gene expression in patients with myotonic dystrophy

Toshiaki Abe, Masami Sato, Junko Kuboki, Tetsuya Kano, Makoto Tamai

Abstract

Aims—Examination of the expression of the mutated allele of myotonic dystrophy protein kinase gene and lens epithelial cell changes in patients with myotonic dystrophy.

Methods—Six eyes from three patients with myotonic dystrophy underwent cataract surgery. The lens epithelium was photographed to examine the morphological changes. mRNAs were extracted to determine myotonic dystrophy protein kinase gene expression in the lens epithelium and peripheral blood. Age matched lens epithelial cells from senile cataracts were used as controls.

Results—All eyes showed iridescent or posterior subcapsular lens opacity. The expression of the myotonic dystrophy protein kinase gene with trinucleotide repeat expansion was evaluated by reverse transcriptase polymerase chain reaction, Southern blotting, and sequence analysis. Lens epithelial cell densities were extremely reduced in the patients compared with the control group.

Conclusion—To the authors' knowledge, this is the first report to describe the relation between lens epithelial cell changes and mutated gene expression in patients with myotonic dystrophy. The gene may be mitotically unstable in the lens epithelial cells; it may influence cell density and lens epithelial function, and it may lead to the development of typical subcapsular lens opacity.

(*Br J Ophthalmol* 1999;83:452-457)

Ocular changes in affected patients can include cataract, ocular hypotony, retinal pigmentary changes of a butterfly or reticular shape, and peripheral polygonal changes.⁷ Cataract has been thought to be the minimal sign of the disorder, and many investigations of the relation between cataract and the disorder have been conducted. Occasionally, the cataract may help diagnose the disorder initially before the clinical sign of myotonia is symptomatic or is just minimal.⁸

The single layer of lens epithelial cells is involved in maintaining the physiology of the lens and is the most active part of the structure. The cells are essential to the continuous propagation of new lens fibres. Damage to or senile changes of the lens epithelium are thought to affect the physiology of the underlying lens fibre mass and contribute to cataract formation. Other authors have also reported that the main source of posterior and anterior subcapsular opacification is lens epithelial cells.⁹⁻¹⁰ The morphology of the lens epithelium is reportedly different among several types of cataracts.¹¹⁻¹² Cataracts in patients with MD have typical opacification, sometimes called multicoloured iridescent cortical opacity and posterior subcapsular cataract.¹³ However, no reports have studied the morphological details of the lens epithelium of cataracts in patients with MD. There has also been no direct evidence relating to the mutated gene expressions in the lens epithelium in patients with MD. We report here the relation between lens epithelial cell changes in patients with MD and DMPK gene expression in the lens epithelium with expanded allele of the CTG trinucleotide repeat.

Myotonic dystrophy (MD) is the most prevalent autosomal dominantly inherited neuromuscular disease in adults. It is characterised by myotonia, with progressive skeletal muscle wasting, intellectual impairment, and cardiac conduction defects.¹ The disorder is mild in late adult onset MD, but sometimes fatal in the congenital form. The incidence of the disorder is approximately 1 in 8000 in white people.¹ MD has been shown to result from the expansion of a CTG repeat in the 3' end of the gene, segregating with a 19q13.3 locus.²⁻⁴ The gene encodes a polypeptide that is a member of the protein kinase family and is called myotonic dystrophy protein kinase (DMPK) gene.⁵ The CTG repeat of the 3' end is extremely expanded in the congenital form, especially when it is transmitted maternally, and shows severe clinical manifestation, the phenomenon of anticipation.²⁻⁶

Patients and methods

Patients from three pedigrees (Fig 1) were examined ophthalmologically and genetically at Tohoku University Hospital, Sendai, Japan. Although patient T-II-4 did not want to talk about her family, all patients in this study were thought to have inherited MD as an autosomal dominant trait. The subsequent ophthalmic examinations included best corrected visual acuity, slit lamp biomicroscopy, specular microscopy, fundus examination, fluorescein angiography, and electroretinography (ERG). Photographs of the cataracts (Fig 2) were taken with use of the slit lamp biomicroscope (Carl Zeiss, model 75SL, Germany). Specular microscopy and data analysis were performed by using Konan specular microscopy Robo-CA (Konan, Tokyo, Japan). The ERG was obtained using a bright white flash in the dark adapted state under controlled conditions that

Department of
Ophthalmology,
Tohoku University
School of Medicine,
Sendai, Miyagi 980,
Japan

T Abe
M Sato
J Kuboki
T Kano
M Tamai

Correspondence to:
Dr T Abe, Department of
Ophthalmology Tohoku
University School of
Medicine, 1-1 Seiryomachi
Aobaku Sendai, Miyagi
980-8594, Japan.

Accepted for publication
22 October 1998

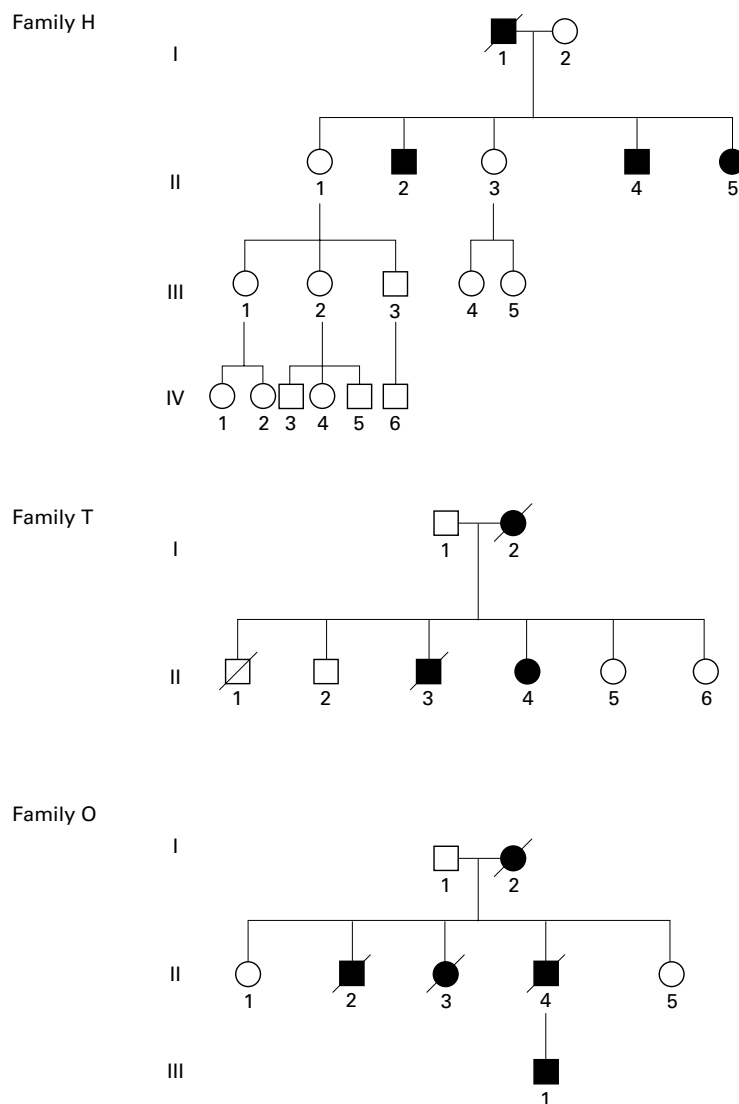


Figure 1 Pedigrees of three families showing generations (roman numerals) of affected (closed symbols) and unaffected (open symbols) members. Squares indicate male members; circles, female; and slash, deceased.

conformed to the standard of the International Standardisation Committee.¹⁴ Phase contrast photographs of the lens epithelium (Fig 3) were taken with the Olympus IMT-2 (Olympus Tokyo, Japan). As soon as possible, we obtained the lens epithelium by continuous circular capsulorhexis (CCC) and prepared it flat on the glass slide. It has been reported that the cell density of lens epithelium does not differ between 2 and 48 hours after removing the lens epithelium with the anterior capsule.¹² Lens epithelial cell densities were calculated by using a cell analyser (Konan Camera Research Institute Inc, Tokyo, Japan).

Informed consent was obtained from all subjects who participated in the study.

EXTRACTION OF MRNA AND POLYMERASE CHAIN REACTION FROM LENS EPITHELIUM

During standard phacoemulsification and aspiration methods for cataract surgery with intraocular lens implantation (IOL), the anterior capsule, including lens epithelial cells, was obtained by CCC. Peripheral blood was ob-

tained at the same time from the subjects who participated in this study. The methods to extract the mRNA have been reported previously.¹⁵ In brief, the cells from the lens epithelium were suspended in extraction buffer (4 M guanidinium thiocyanate and 0.5% N-lauroyl sarcosine), and cleared cellular homogenate by centrifugation was mixed with oligo dT cellulose (Pharmacia Biotech Inc, Uppsala, Sweden). The oligo dT cellulose was washed with high salt buffer (10 mM TRIS-HCl (pH 7.5), 1 mM EDTA, 0.5 M NaCl) for several times followed by low salt buffer (10 mM TRIS-HCl (pH 7.5), 1 mM EDTA, 0.1 M NaCl) several times, and then mRNA was eluted by prewarmed elution buffer (10 mM TRIS-HCl (pH 7.5), 1 mM EDTA). First strand cDNA was generated by random hexadeoxynucleotides at 0.2 µg in each reaction, which was catalysed by Moloney murine leukaemia virus reverse transcriptase (Pharmacia Biotech Inc). With the use of a thermocycler (Perkin Elmer, Norwalk, CT, USA), a polymerase chain reaction (PCR) was carried out in 50 µl of reaction mixture containing 1 µl of the patient's cDNA (described below) of the lens epithelium, 20 µM of each primer (MD-1: 5'-CTTC CCAGGCCTGCAGTTTGCCCATC-3' and MD-2: 5'-GAACGGGGCTCGAAGGGTCC TTGTAGC-3'),⁵ 200 µM each of dATP, dCTP, dGTP, and TTP, 10 mM of KCl, 20 mM of TRIS-Cl (pH 8.8), 2 mM of MgSO₄, 0.1% Triton X-100, and 0.1 mg/ml nuclease free bovine serum albumin, and 5 units of Taq Plus Long polymerase (Stratagene, La Jolla, CA, USA). Reaction cycles were 35. The temperature settings for PCR were 94°C for 1 minute for denaturation, 62°C for 2 minutes for annealing, and 72°C for 2 minutes for polymerisation. In each case, amplified DNA was separated in 1.5% agarose gel (SeaKem, FMC BioProducts, Rockland, ME, USA) containing 0.05 µg/ml ethidium bromide. DNA was visualised with use of an ultraviolet transilluminator. Amplification of β actin was also performed by the same methods described above except that each primer was β1: 5'-CTACAATGAGCTGCGTGTGG-3' and β2: 5'-CGGTGAGGATCTTCATGAGG-3'.

SOUTHERN BLOTTING ANALYSIS

One of the subcloned PCR products was also used as a probe for Southern blotting analysis labelled by digoxigenin (Boehringer, Detroit, MI, USA), as reported elsewhere.¹⁶ In brief, the PCR samples separated in 2% agarose gel were blotted onto a nitrocellulose filter (Toyo, Tokyo, Japan), prehybridised at 68°C, and hybridised at 68°C with the probe described above (10 ng/ml) in 5x SSC (1x SSC=0.15 M NaCl/15 mM Na₃ citrate, pH 7.5), 0.5% sodium dodecyl sulphate, blocking reagent (Boehringer, Detroit, MI, USA), and 100 µg/ml of salmon sperm (Fig 3).

SEQUENCE ANALYSIS

One of the amplified PCR products of each patient was cut out from the gel and purified by the standard protocol (BIO 101 Inc, La Jolla, CA, USA), following subsequent subcloning

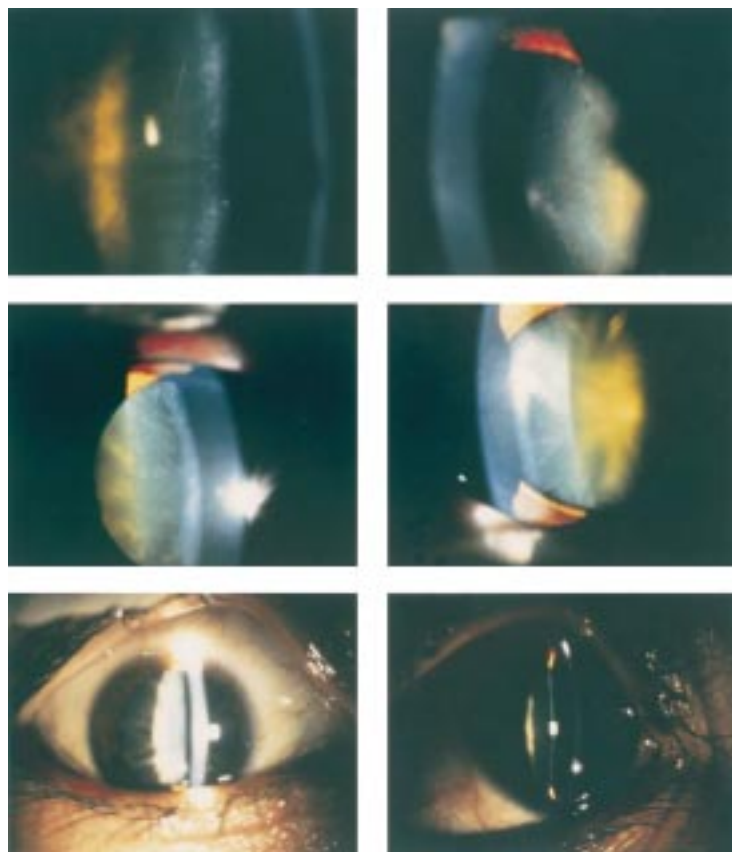


Figure 2 Photographs of cataracts were taken in affected patients. Patient H-II-2 (top; right and left are right eye and left eye, respectively) is a 59 year old man; patient T-II-4 (middle; right and left eyes) is a 58 year old woman; and patient O-III-1 (bottom; right and left eyes) is a 33 year old man. All showed either cortical iridescent opacity or posterior cortical opacity. Patients are described in the text.

into a T-vector¹⁷ (Promega, Madison, WI, USA). Subcloned PCR products were then sequenced with an automatic DNA sequencer (Pharmacia LKB ALF DNA sequencer, Pharmacia, Uppsala, Sweden) from both ends of the PCR product using a dideoxy chain termination protocol.¹⁸

STATISTICAL ANALYSIS

We studied patients and age matched control subjects with senile cataract (eight eyes of healthy control subjects; average age 56.7 years) for lens epithelial cell density. Lens epithelial cell density was statistically analysed with a paired *t* test.

Results

PATIENTS

A 59 year old man (case H-II-2) noticed muscle weakness and gait disturbance at age 43 years. Left complete bundle branch block was observed by electrocardiography (ECG). When the patient consulted us on 25 June 1997, his best corrected visual acuity was light sensitivity (nc) in his right eye and hand movements (nc) in the left. Eye movements and pupil reactions were normal. Intraocular pressure (IOP) was 11 mm Hg in both eyes. Multi-coloured and cortical iridescence of the lens was observed by biomicroscopic examination of both eyes (Fig 2). Fundus examination after cataract operation revealed reticular changes of retinal pigment epithelium in the mid-periphery of the retina. The oscillatory potentials (OPs) and b-wave of the ERG showed attenuation in both eyes. Specular microscopy disclosed that cell density of his corneal endothelium was 3676 cells/mm² in the right eye and 3095 cells/mm² in the left (Table 1). Lens epithelial cell density was 3208 cells/mm² in the right eye and 3144 cells/mm² in the left (Fig 3) by the methods described.

A 58 year old woman (case T-II-4) noticed muscle weakness of the right leg and lower extremity at age 37 years. Right ventricle hypertrophy and left ventricle global hypokinesis were shown by echocardiography and intra-ventricular conduction delay, flat T, and abnormal Q by ECG. When she consulted us at age 51 years, her visual acuity was 0.3 right eye with a cylinder of -3.0 dioptres \times 170 refraction and 0.4 (nc) in the left eye. We could find no nystagmus, but dysmetria and convergence insufficiency were observed. She had mild palpebral ptosis in her left eye. Pupil reactions were normal. IOP was 10 mm Hg in both eyes. Cortical iridescence of the lens was observed by biomicroscopic examination of both eyes (Fig 2). Fundus examination showed reticular degeneration at the posterior pole of the retina. The OPs of ERG were attenuated. Corneal endothelial cell density was 2865 cells/mm² in the right eye and 3044 cells/mm² in the left by specular microscopy (Table 1). Cataract surgery with IOL insertion was performed on 29 October 1996, in the left eye and on 23 November in the right eye. Lens epithelial cell density was 2506 cells/mm² in

Table 1 Ophthalmic findings in patients with myotonic dystrophy*

Patients	Age/ duration/ sex	Visus pre/post operation	Lens opacity	Retinal changes	ERG	Corneal CD (cells/mm ²)	Lens CD (cells/mm ²)	Myotonia/ heart abnormality
1 H-II-2	59/16/M	LS/0.6 HM/0.7	MCIO MCIO	+	OPsA	3676 3095	3802 3144	+/+
2 T-II-4	58/21/F	0.3/0.9 0.4/1.0	MCIO MCIO	+	OPsA	2865 3044	2506 2849	+/+
3 O-III-1	33/2/M	0.06/1.0 0.03/1.0	PSCO PSCO	-	OPsA	3620 2868	1326 1543	+/+

*Age/duration/sex indicate the age and sex of the patients and duration of the disease; visus pre/post operation: best corrected visual acuity before and after operation; ERG=electroretinogram; corneal CD= corneal endothelial cell density; lens CD= lens epithelial cell density; myotonia and heart abnormality= patients who showed muscle weakness or myotonia in any other place in the body or who had heart abnormalities detected by electrocardiogram or cardioechography; LS=light sensitivity; HM= hand movements; MCIO=multicoloured iridescent opacity; PSCO= posterior subcapsular opacity; OPsA=attenuated oscillatory potentials; the lens CD in patients with MD (average 2274 cells/mm²) was statistically significant, compared with controls with senile cataracts (average 4627 cells/mm²) (p=0.004).




Figure 3 Examination of lens epithelial cell density reveals that all MD patients with cataract show extremely decreased cell densities, compared with the age matched normal subject. Lens epithelium of patient T-II-4 (top; right and left are right eye and left eye, respectively), a 58 year old woman; patient H-II-2 (second from top; right and left eyes), a 59 year old man; patient O-III-1 (second from bottom; right and left eyes), a 33 year old man; control subject with senile cataract (bottom right), a 78 year old man and also other control subject with senile cataract (bottom left), a 58 year old man. Actual cell density is shown in Table 1.

the right eye and 2849 cells/mm² in the left (Fig 3) by the methods described.

A 33 year old man (case O-III-1) noticed muscle weakness and myotonia of his lower distal extremity and gait disturbance for 2 years. When he consulted us, he showed frontal baldness and a haggard appearance. He also demonstrated below average intelligence and slurred speech. His best corrected visual acuity was 0.06 right eye (nc) and 0.03 left eye (nc). Pupil reactions were normal, and IOP was 12 mm Hg on both eyes. Posterior cortical lens opacity was observed by biomicroscopic examination of both eyes (Fig 2). Fundus examination was difficult before surgery because of the lens opacity, but funduscopy revealed no abnormalities after surgery. He refused to undergo fluorescein angiography. The waves of the ERG showed mild attenuation of the b-wave and OPs. Specular microscopy showed

that cell density of his corneal endothelium was 3620 cells/mm² in the right eye and 2868 cells/mm² in the left (Table 1). Lens epithelial cell density was 1326 cells/mm² in the right eye and 1543 cells/mm² in the left (Fig 3) by the methods described.

Corneal endothelial cell density was not statistically significant between patients with MD and control subjects; conversely, statistically significant decreases ($p < 0.01$; $p = 0.004$) in cell density in the lens epithelium in patients with MD (average 2274 cells/mm²) were found, when compared with control subjects (cell densities were between 4255 and 5813 cells/mm²; average 4627 cells/mm²), whose cell densities were within cell densities reported elsewhere (Fig 3).¹²⁻¹⁹

We extracted mRNA from the lens epithelium and peripheral blood of MD patients and amplified β actin by reverse transcriptase polymerase chain reaction (RT-PCR) are shown in Figure 4A. Although the products of the β actin from the lens epithelium seemed to be fainter than blood, especially in patient H-II-2, we also amplified the mutated allele of the DMPK gene and the normal allele of the gene by RT-PCR and Southern blotting analysis (Fig 4B). In addition to the normal allele of the gene (128 bp), multiple larger bands (Fig 4B) were observed in the lens epithelium and peripheral blood of the patients. We could not amplify these bands in the control group in both lens epithelium (NP in Fig 4B) and peripheral blood (not shown). Multiple bands in the lens epithelium in the patients also seemed to be larger than those of peripheral bloods (Fig 4B).

In order to confirm the nucleotide sequences of the larger bands, we performed sequence analysis. The PCR product marked by an asterisk was subcloned and sequenced. It was shown that these bands were generated by the expansion of CTG repeat in the DMPK gene by sequence analysis (T-II-4 in Fig 5). The flanking sequences of the CTG expansion in both 5' and 3' ends of the gene were also confirmed to correlate to the DMPK gene.

Discussion

The genetic disorder of MD has been linked to the long arm of 19q with expanded CTG repeats in the gene.² The repeats of the gene from 282 normal alleles surveyed have numbered 5 (48%), with the largest being 27. Minimally affected patients have at least 50 copies. The gene has been thought to be expressed in many tissues, but the somatic mosaicism²⁻²⁰ has been reportedly unstable and age dependent. The CTG repeat length increases over time, indicating continuing mitotic instability.²¹ The expansion was calculated to expand about 100 base pairs in 5 years.²⁰ The phenomenon was believed to explain the progress of the clinical disorder.

Several genetic conditions caused by trinucleotide repeat expansion have been documented and some showing anticipation have been reported in several neurological disorders.²²⁻²⁷ Ocular changes associated with a trinucleotide repeat expansion have also been

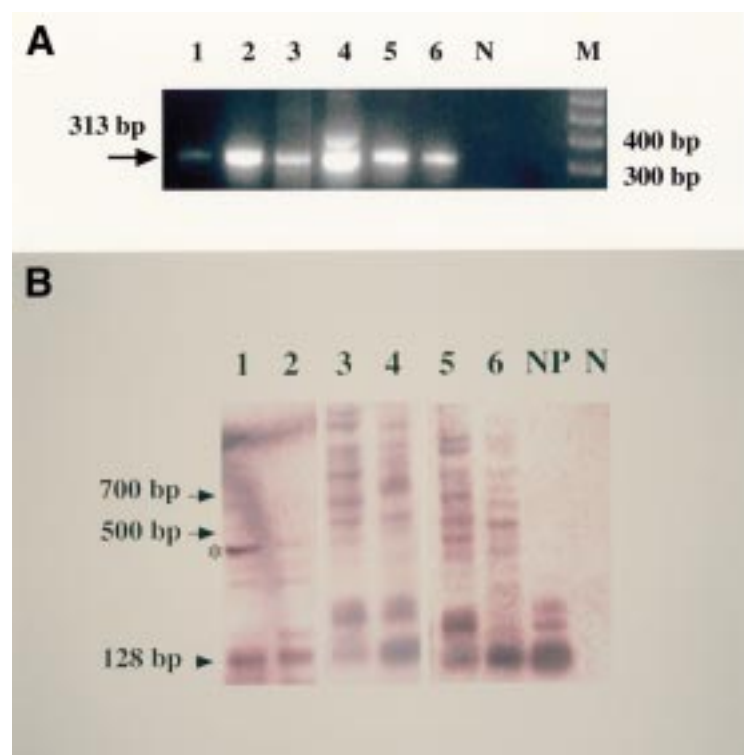


Figure 4 Results of reverse transcriptase polymerase chain reaction (RT-PCR) and Southern blotting analysis from affected patients in the families. (A) Results of β actin from lens epithelial cells and peripheral blood from patients. Patient H-II-2 (Nos 1 and 2 indicate lens epithelial cells and peripheral blood, respectively) is a 59 year old man; patient T-II-4 (Nos 3 and 4, same as above) is a 58 year old woman; and patient O-III-1 (Nos 5 and 6, same as above) is a 33 year old man. The negative control is indicated by N. M is a marker of the 100 base pair ladder. (B) Results of myotonic dystrophy protein kinase gene. Normal band is indicated by arrowhead; extended bands, arrows. The normal control (NP) show no mutated band; conversely, mutated bands occur in all affected members examined. The extended band, which was shown by an asterisk, was subcloned and sequenced.

reported in patients with spinocerebellar ataxia type 1 (SCA1).²⁸ Interestingly, patients carrying trinucleotide repeat expansion of SCA1 gene show enlargement and decreased cell density of the corneal endothelium. They do not exhibit typical lens opacity. The corneal endothelial cell densities in patients with MD

were within normal limits (Table 1), compared with normal healthy controls²⁹ (data not shown), but showed decreased cell density in the lens epithelium with typical lens opacity. Lens epithelial cells may be influenced by continuing mitotic instability of the gene in lens epithelial cells and may have shown decreased cell density. Conversely, corneal endothelial cells, which do not proliferate through life, may show normal cell density.

Histological or morphological changes in the muscle or central nervous system in patients with MD have been reported.³⁰ Interestingly, from the results of the lens epithelial cell density, the decrease of the cell density seemed to be dependent on the age at which the clinical symptoms started (Table 1). A marked decrease in lens epithelial cell densities was also observed in our patients, especially in patient O-III-1. He was younger (33 years old) than the other patients studied and his clinical symptoms started earlier than theirs. We believe that the clinical symptoms were more severe in this patient. The abnormality may have been influenced by the mutated allele of the DMPK gene. Enlargement of cell size also was reported at the edge of CCC after cataract surgery with IOL.³¹ The results indicated that the lens epithelial cell changes were severe at surgical trauma and on the portion in contact with the IOL. Konofsky and coworkers¹⁹ reported that cell density of lens epithelium in non-MD patients with subcapsular opacity appeared to be lower than on the epithelium in nuclear cataract. They speculated that the lens epithelial cells play an important role in generating subcapsular lens opacity. The type of lens opacity reported so far in patients with MD, including our cases, also show cortical opacity such as iridescent cortical opacity or posterior subcapsular opacity and may be influenced by the lens epithelial cells. Increased cell size and decreased cell density have also been produced by aging, trauma, inflammation, or surgery in corneal endothelium.³² Rao and coworkers

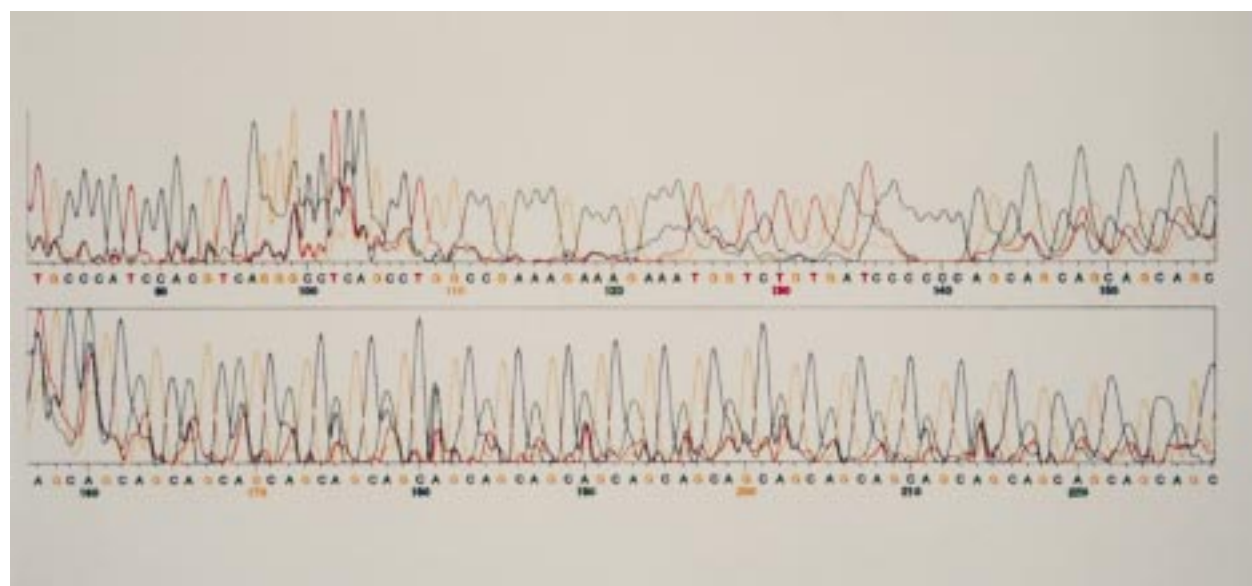


Figure 5 Result of the sequence of the subcloned DNA, which was amplified from the cDNA of the lens epithelium in patient T-II-4 (shown by an asterisk in Fig 4B[f4]). Abnormal CAG repeat, the reverse sequence of CTG, was observed in the amplified DNA.

reported that significant correlation was found between cell size or density and development of postoperative corneal oedema.³³ So decreased cell density may also correlate with the lens epithelial cell function and may influence the generation of the lens opacity specific to MD. However, there have been no reports describing the expression of the mutated gene in the lens epithelium in patients with MD, although simple loss or gain of expression of DMPK may not be the only crucial requirement for development of the disease.^{34 35}

In this study, we showed the expression of mutated allele of the DMPK gene and the normal allele of the gene by RT-PCR, Southern blotting, and sequence analysis in the lens epithelium. As others have reported, these multiple bands may indicate somatic mosaicism²¹ or they may be due to PCR artefact. However, we confirmed that these bands were generated by the expansion of CTG repeat in the DMPK gene by sequence analysis (Fig 5). Also, we could not amplify these bands in the control group (NP in Fig 4). Although multiple larger bands were observed in both lens epithelium and peripheral blood, the multiple bands in the lens epithelium in the patients seemed to be larger than those of peripheral blood. These results may also indicate the somatic instability of the DMPK gene. It is also possible that these characteristics may be due to an extremely low expression of the mutated allele of the gene, especially in patients who have longer repeats.³⁶ Further study may be necessary to elucidate the correlation of the length of the expansion of the trinucleotide repeat of DMPK gene and cataract formation.

This work was supported in part by grants from the Japanese Retinitis Pigmentosa Society (TA); from the Ministry of Education and Culture of the Japanese Government, Tokyo; and the Research Committee on Chorioretinal Degenerations, the Ministry of Health and Welfare of the Japanese Government, Tokyo (MT).

We thank Ms Maxine A Gere for checking the manuscript.

- 1 Harper PS. *Myotonic dystrophy*. 2nd ed. London: Saunders, 1989.
- 2 Brook JD, McCurrach ME, Harley HG, et al. Molecular basis of myotonic dystrophy: expansion of trinucleotide (CTG) repeat at the 3' end of a transcript encoding a protein kinase family member. *Cell* 1992;68:799–808.
- 3 Fu YH, Pizzuti A, Fenwick Jr RG, et al. An unstable triplet repeat in a gene related to myotonic muscular dystrophy. *Science* 1992;255:1256–8.
- 4 Mahadevan M, Tsilifidis C, Sabourin L, et al. Myotonic dystrophy mutation: an unstable CTG repeat in the 3' untranslated region of the gene. *Science* 1992;255:1253–5.
- 5 Meiner A, Wolf C, Carey N, et al. Direct molecular analysis of myotonic dystrophy in the German population: important considerations in genetic counselling. *J Med Genet* 1995;32:645–9.
- 6 Harper PS, Dyken PR. Early onset dystrophia myotonica—evidence supporting a maternal environmental factor. *Lancet* 1972;2:53–5.
- 7 Kimizuka Y, Kiyosawa M, Tamai M, et al. Retinal changes in myotonic dystrophy. Clinical and follow-up evaluation. *Retina* 1993;13:129–35.
- 8 Kidd A, Turnpenny P, Kelly K, et al. Ascertainment of myotonic dystrophy through cataract by selective screening. *J Med Genet* 1995;32:519–23.
- 9 von Sallmann L. The lens epithelium in the pathogenesis of cataract. *Am J Ophthalmol* 1957;44:159–70.

- 10 Streeten BW, Eshaghian J. Human posterior subcapsular cataract: a gross and flat preparation study. *Arch Ophthalmol* 1978;96:1653–8.
- 11 Vasavada AR, Cherian M, Yadav S, et al. Lens epithelial cell density and histomorphological study in cataractous lenses. *J Cataract Refract Surg* 1991;17:798–804.
- 12 Saitoh J, Nishi O, Hitani H. Cell density and hexagonality of lens epithelium in human cataracts. *Nippon Ganka Gakkai Zasshi* 1990;94:176–80.
- 13 Burian HH, Burns CA. Ocular changes in myotonic dystrophy. *Am J Ophthalmol* 1967;63:22–34.
- 14 Mormor MF, Arden GB, Nilsson SEG, et al. Standard for clinical electroretinography. *Arch Ophthalmol* 1989;107:816–9.
- 15 Abe T, Durlu YK, Tamai M. The properties of the retinal pigment epithelial cells in proliferative vitreoretinopathies compared to the cultured human retinal pigment epithelial cells. *Exp Eye Res* 1996;63:201–10.
- 16 Abe T, Tsuchida K, Tamai M. A comparative study of the polymerase chain reaction and local antibody production in acute retinal necrosis syndrome and cytomegalovirus retinitis. *Graefes Arch Clin Exp Ophthalmol* 1996;234:419–24.
- 17 Holton TA, Graham MW. A simple and efficient method for direct cloning of PCR products using ddT-tailed vectors. *Nucl Acids Res* 1991;19:1165.
- 18 Sanger F, Coulson AR, Barrel GBG, et al. Cloning in single-stranded bacteriophage as an aid to rapid DNA sequencing. *J Mol Biol* 1980;63:22–34.
- 19 Konofsky K, Naumann GOT, Guggenmoos-Holzmann I. Cell density and sex chromatin in lens epithelium of human cataracts. Quantitative studies in flat preparation. *Ophthalmology* 1987;94:875–80.
- 20 Wong LJC, Ashizawa T, Monckton DG, et al. Somatic heterogeneity of the CTG repeat in myotonic dystrophy is age and size dependent. *Am J Hum Genet* 1995;56:114–22.
- 21 Martorell L, Martinez JM, Carey N, et al. Comparison of CTG repeat length expansion and clinical progression of myotonic dystrophy over a five year period. *J Med Genet* 1995;32:593–6.
- 22 Koide R, Ikeuchi T, Onodera O, et al. Unstable expansion of CAG repeat in hereditary dentatorubral-pallidoluysian atrophy (DRPLA). *Nat Genet* 1994;6:9–13.
- 23 Kawaguchi Y, Okamoto T, Taniwaki M, et al. CAG expansion in a novel gene for Machado-Joseph disease at chromosome 14q32. *Nat Genet* 1994;8:221–8.
- 24 Orr HT, Chung M, Banfi S, et al. Expansion of an unstable trinucleotide CAG repeat in spinocerebellar ataxia type 1. *Nat Genet* 1993;6:221–6.
- 25 Verkerk AJMH, Pieretti M, Sutcliffe JS, et al. Identification of a gene (FMR-1) containing a CGG repeat coincident with a break point cluster region exhibiting length variation in fragile X syndrome. *Cell* 1991;65:905–14.
- 26 Hunchington's Disease Collaborative Research Group. A novel gene containing a trinucleotide repeat that is expanded and unstable on Hunchington's disease chromosomes. *Cell* 1993;72:971–83.
- 27 La Spada AR, Wilson EM, Lubahn DB, et al. Androgen receptor gene mutations in X-linked spinal and bulbar muscular atrophy. *Nature* 1991;352:77–9.
- 28 Abe T, Abe K, Aoki M, et al. Ocular changes in patients with spinocerebellar degeneration and repeated trinucleotide expansion of spinocerebellar ataxia type 1 gene. *Arch Ophthalmol* 1997;115:231–6.
- 29 Abe T, Nakazawa M, Kimizuka Y, et al. Factors influencing endothelial damage of the cornea in diabetic patients. *Atarashii Ganka* 1990;7:1647–51.
- 30 Tohgi H, Kawamorita A, Utsugisawa K, et al. Muscle histopathology in myotonic dystrophy in relation to age and muscular weakness. *Muscle Nerve* 1994;17:1037–43.
- 31 Hara T, Hara T. Panoramic specular microscopy of lens epithelial cells in the postoperative pseudophakic eye. *J Cataract Refract Surg* 1992;18:589–93.
- 32 Bourne WM, Kaufman HE. Specular microscopy of human corneal endothelium in vivo. *Am J Ophthalmol* 1976;81:319–26.
- 33 Rao GN, Aquavella JV, Goldberg SH, et al. Pseudophakic bullous keratopathy. Relationship to preoperative corneal endothelial status. *Ophthalmology* 1984;91:1135–40.
- 34 Reddy S, Smith DB, Rich MM, et al. Mice lacking the myotonic dystrophy protein kinase develop a late onset progressive myopathy. *Nat Genet* 1996;13:325–35.
- 35 Jansen G, Groenen PJ, Bachner D, et al. Abnormal myotonic dystrophy protein kinase levels produce only mild myopathy in mice. *Nat Genet* 1996;13:316–24.
- 36 Carango P, Noble JE, Marks HG, et al. Absence of myotonic dystrophy protein kinase (DMPK) mRNA as a result of a triplet repeat expansion in myotonic dystrophy. *Genomics* 1993;18:340–8.