

LETTERS TO THE EDITOR

Uveitis associated with parvovirus infection

EDITOR,—Parvovirus B 19 is a common infection in developed countries with a seroprevalence of 40–60% in young adults.¹ The commonest age of infection is 5–14 years. Clinical features of acute infection include erythema infectiosum (slapped cheek syndrome or Vth disease), arthralgia, and fever. It is usually a mild disease, but aplastic anaemia may develop in susceptible hosts and it may cause fetal loss if acquired during pregnancy. Acute infection can be accompanied by autoantibody formation including antinuclear antibodies (ANA) and rheumatoid factor (RF)² and therefore infection may share clinical and serological similarities with early rheumatoid arthritis and juvenile chronic arthritis. Uveitis in young girls usually occurs in association with early onset pauciarticular juvenile chronic arthritis which has a high frequency of ANA in the absence of RF. We report a case of uveitis in a young girl, associated with a transient ANA and RF, and serological evidence of acute parvovirus infection.

CASE REPORT

A 6 year old white girl presented with a 2 week history of a painful red left eye. She had an unaided visual acuity of 6/9 in each eye; there was a left anterior uveitis with 3+ anterior chamber cells. The uveitis was non-granulomatous with no keratic precipitates, band keratopathy, synechiae, or flare; she had a mild vitritis but no macular oedema or choroidal involvement.

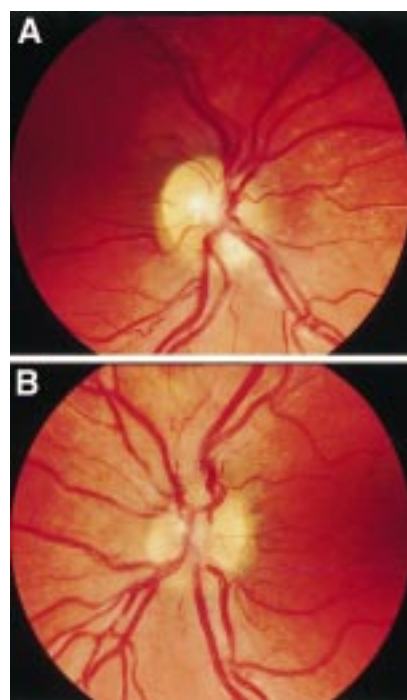


Figure 1 Mild disc oedema, 14 months after onset of the uveitis. (A) Right eye, (B) left eye.

Table 1 Summary of serological abnormalities

Month after onset of uveitis	RF	ANA	Lymphocytes ($\times 10^9/l$)	Parvovirus
1	+	—	5.7	
4	—	—	3.5	IgM+ IgG+
12	—	Weakly +		IgM—
18	—		4.4	IgM— IgG+

Her medical history included an unspecified viral illness requiring brief hospital admission at 1 year of age from which she fully recovered. When 5 years old she developed recurrent otitis media and 6 months later underwent grommet insertion for glue ear. She developed tonsillitis and pharyngitis at 6 years associated with serological evidence of infectious mononucleosis. Her grandmother had rheumatoid arthritis, but there was no other family history of relevance.

She had a 2 year history of knee pains but had no other systemic symptoms at the onset of the uveitis.

She was treated with topical steroids and cycloplegia; after 2 months she developed mild disc oedema and hypotony with intraocular pressures of 11 mm Hg right eye, 4 mm Hg left eye. Her acuity remained 6/9 in each eye, and she continued topical steroid treatment only. Ten months after onset she developed a painful right anterior uveitis, mild uveitis persisting in the left eye. Fourteen months after onset both eyes had mild panuveitis (anterior uveitis, mild vitritis, and mild disc oedema, see Fig 1); the hypotony had resolved. Visual acuity remained normal and topical steroids were withdrawn 23 months after onset when all signs of inflammation had receded. There have been no recurrences at last review 27 months after onset.

Repeated rheumatological examinations did not reveal any inflammatory arthritis, and her knee pains ascribed to hypermobility syndrome.

The following were normal or negative: C reactive protein (CRP), immunoglobulins, neutrophil count, liver function tests, serum angiotensin converting enzyme (ACE), anti-double stranded DNA antibodies, and titres for adenovirus, *Chlamydia psittaci*, hepatitis B, enterovirus, mumps, measles, herpes simplex, varicella zoster, and cytomegalovirus. There was evidence of previous infection with rubella, Epstein-Barr virus, and streptococci.

Abnormal investigations included a persistent mild lymphocytosis. The RF was positive at the onset of uveitis (24 MRF units/ml, >20 = strongly positive) but undetectable thereafter. Parvovirus IgM was positive (18 units macroelisa) at 4 months after onset, but negative thereafter (Table 1). One year after onset she had a weakly positive ANA of the nucleolar pattern.

COMMENT

Parvovirus infection has been associated with transient neurological disease including encephalitis,³ aseptic meningitis,⁴ neuroretinitis with disc oedema,⁵ ciliary ganglionitis and disc hyperaemia,⁶ and immune mediated inner ear disease.⁷ There have been no previous reports of an isolated uveitis. Our patient developed a painful chronic bilateral panuveitis and arthralgia associated with IgM antibodies to parvovirus that were detectable 3 months after onset of disease and absent thereafter. As IgM antibodies subside within 3 months of an acute infection it is likely that an acute parvovirus infection occurred at the onset of the uveitis. This allows us to postulate a causal link between the infection and the

uveitis, this is not proved and another aetiological agent for the uveitis cannot be excluded. Other causes of uveitis in children include ankylosing spondylitis, trauma, toxoplasmosis, toxocariasis, pars planitis, and masquerade syndromes; Behçet's syndrome, sarcoid, Fuchs' heterochromic cyclitis, herpes simplex, and Vogt-Koyanagi-Harada are less common in younger children.

Acute parvovirus infection is known to trigger the production of autoantibodies and RF; in one study 7/53 patients developed ANA and 1/53 developed RF.² Antibodies against immunodominant parvovirus peptides cross react with keratin, collagen type II, single strand DNA, and cardiolipin in humans; immunisation of mice with these peptides produce a similar pattern of autoantibodies.⁸ The seroprevalence of IgG antibodies to parvovirus has been found higher in patients with juvenile rheumatoid arthritis and rheumatoid arthritis (RA) in some studies but not in others.^{9,10} The arthritis associated with acute infection may only involve a few joints and most commonly involves the knee. It can therefore mimic early onset pauciarticular juvenile chronic arthritis (JCA) as well as RA.¹¹ The differential diagnosis of acute parvovirus infection and autoimmune arthritis is sometimes only possible after exclusion of an acute parvovirus infection by examination of the changes in IgM parvovirus response.

Although most parvovirus infections resolve in a few weeks, joint symptoms may persist for several months. Recurrence of acute symptoms has also been recorded 7 years later.¹² Persistent viral DNA has been found in blood, marrow erythroid precursors, and synovium,¹³ but viral DNA may persist without clinical disease.^{10,12,13} More recently evidence has emerged of parvovirus VP-1 antigen persistence in the synovium of a high proportion (30/39) of RA patients with some markers of infectivity present in this tissue.¹⁴ It is possible that virus may persist in the eye, but the delayed onset of disease in the second eye in our case suggests that haematogenous spread was the more likely route of transmission than the activation of dormant intraocular virus.

De Boer *et al*⁵ examined the intraocular fluids of six patients with intermediate uveitis and IgG antibodies to parvovirus in their serum. None showed evidence of intraocular antibody production, but the report did not state whether the patients ever had clinical signs of acute parvovirus infection or whether seroconversion coincided with the onset of uveitis in these patients.

Uveitis associated with ANA + JCA is almost universally a painless anterior disease without significant disc oedema or vitritis. Our case presented with a painful, red anterior uveitis later associated with a mild vitritis and disc oedema. The only other case of parvovirus uveitis described was also a bilateral panuveitis with disc involvement but was painless and caused tonic pupils.⁶ Calvert describes a case of unilateral neuroretinitis in a patient with AIDS that occurred during a parvovirus infection.⁵ Our case did not have a uveitis typical of JCA and the absence of joint inflammation or persistent JCA make it unlikely that JCA was the cause.

The incidence of uveitis in those under 10 years is low compared with adults with an age corrected incidence of 3/100 000 compared with 23/100 000 in adults (unpublished figures). A girl in the same school class as our patient developed a painful acute anterior uveitis within 1 month of the onset of disease in our index patient. She had no evidence of recent or previous parvovirus infection or any systemic inflammatory disease. It is possible that another infectious organism caused both cases.

R MAINI
C EDELSTEN
Department of Ophthalmology, Ipswich Hospital,
Ipswich, Suffolk IP4 5PD

Correspondence to: Mr R Maini, Department of Ophthalmology, Addenbrooke's Hospital, Cambridge CB2 2QQ

Accepted for publication 31 May 1999

- 1 Kerr JR. Parvovirus B19 infection. *Eur J Clin Microbiol Infect Dis* 1996;15:10-29.
- 2 Kerr JR, Boyd N. Autoantibodies following parvovirus B19 infection. *J Infect* 1996;32:41-7.
- 3 Balfour HH, Schiff GM, Bloom JE. Encephalitis associated with erythema infectiosum. *J Pediatr* 1970;77:133-6.
- 4 Koduri PR, Naides SJ. Aseptic meningitis caused by parvovirus B19. *Clin Infect Dis* 1995;21:1053.
- 5 Calvert P. In Miller N R, ed. *Walsh and Hoyt's clinical neuro-ophthalmology*. Baltimore: Williams and Wilkins, 1995;5:3981.
- 6 Corridan PGJ, Laws DE, Morrell AJ, et al. Tonic pupils and human parvovirus B19 infection. *J Clin Neuro-ophthalmol* 1991;11:109-10.
- 7 Cotter CS, Singleton GT, Corman LC. Immune mediated inner ear disease and parvovirus B19. *Laryngoscope* 1994;104:1235-9.
- 8 Lunardi C, Tiso M, Borgato L, et al. Chronic parvovirus B19 infection induces the production of antiviral antibodies with auto-antigen binding properties. *Eur J Immunol* 1998;28:936-48.
- 9 Kishore J, Misra R, Gupta D, et al. Raised antibodies to parvovirus B19 in juvenile rheumatoid arthritis. *Ind J Med Res* 1998;107:15-18.
- 10 Soderlund M, von Essen R, Haapasari J, et al. Persistence of parvovirus B19 in synovial membranes of young patients with and without chronic arthropathy. *Lancet* 1997;349:1063-5.
- 11 Naides SJ. Parvovirus B19 infection. *Rheum Dis Clin North Am* 1993;19:457-75.
- 12 Sasaki T, Murai C, Tai M, et al. Persistent infection of human parvovirus B19 in a normal subject. *Lancet* 1995;346:851.
- 13 Nikkari S, Roivainen A, Hannonen P, et al. Persistence of parvovirus B19 in synovial fluid and bone marrow. *Ann Rheum Dis* 1995;54:597-600.
- 14 Takahashi Y, Murai C, Shibata S, et al. Human parvovirus as a causative agent for rheumatoid arthritis. *Proc Natl Acad Sci USA* 1998;95:8227-32.
- 15 De Boer JH, De Keizer RJ, Kijlstra A. In search of intra-ocular antibody production to parvovirus B19 and adenovirus in intermediate uveitis (letter). *Br J Ophthalmol* 1993;77:829.

Management of corneal opacification associated with epibulbar choristomata

EDITOR.—Choristomas are the commonest limbal tumours in children.¹ Four types are recognised—dermoid, dermolipoma, single tissue, and complex choristoma. They arise from metaplastic transformation in the mesoblast lying between the optic nerve and the surface ectoderm. Epithelial and dermal, neural, cartilaginous, smooth muscle, lacrimal, sweat, or sebaceous gland tissue may be present.²⁻⁴ They are well circumscribed, white or pale yellow, and may be single or multiple, unilateral, or bilateral⁵ or form a ring.³ Occasionally, epibulbar choristomata are associated with superficial corneal involvement characterised by a vascularised pannus particularly in those containing lacrimal tissue.⁶

CASE 1

A 7 year old Malaysian Chinese boy was referred to one of us (CL) with cloudy corneas since birth. His vision had always been poor but no strabismus developed. The pregnancy and developmental history were otherwise normal. There was no family history of ocular disease.

Examination revealed 6/18 part vision right and 6/36 left. Bilateral nasal epibulbar dermoids and reticular anterior stromal opacification were noted (Fig 1A).

Neither refraction nor a diagnostic contact lens improved vision. A left 7.5 mm lamellar corneal graft was secured onto a 7.5 mm bed with 16 interrupted, 10-0 nylon sutures. The graft epithelialised over 5 days, under Chloromycetin (chloramphenicol) cover.

The right eye was then patched for 6 hours daily. The sutures were removed at 6 weeks, and his vision improved to 6/18 right (4.00/-5.00 × 20) and 6/18 left (-1.75/-1.25 × 35).

Patching was continued and the patient was discharged to the referring hospital. Histopathology (Fig 1B) showed stromal opacification to a quarter thickness with a large number of vessels in the superficial stroma. The vessels are abnormal having only a single layer of endothelium and little other murine structure.

CASE 2

A 9 week old prematurely born white boy presented with an unsightly lump on his right eye. There were no other congenital abnormalities noted. A maternal uncle had a mass removed from one of his eyes, the nature of which was not known.

Examination revealed a small pale, yellow tumour 3 mm in diameter, on the superonasal limbus of the right eye with an adjacent corneal pannus (Fig 2A). The left eye was normal. Limbal dermoid was diagnosed and excised at 1 year of age. The eye healed well, with a small residual corneal scar. The corneal pannus was not removed and remained static (Fig 2A). Histopathology showed a goblet cell containing stratified, squamous, non-keratinising epithelium, overlying a spindle cell lesion, which embraces islands of adipose tissue and occasional sweat gland elements.

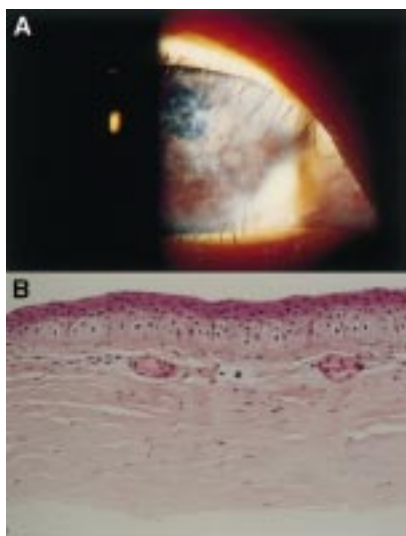


Figure 1 Case 1. (A) Temporal epibulbar choristomata with reticular anterior stromal opacification. (B) Histology from superficial keratectomy, demonstrating irregular keratinised epithelium and vascularised stromal tissue. Magnification ×400.

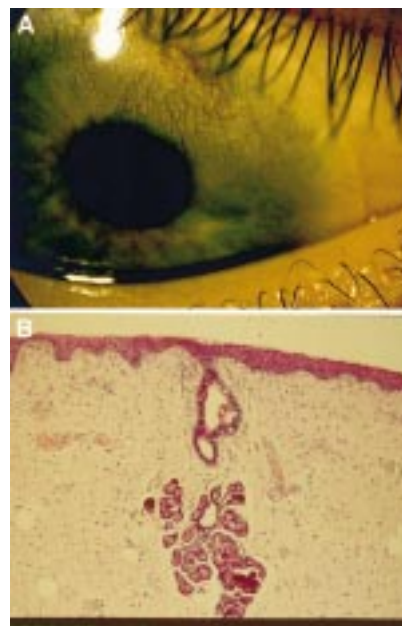


Figure 2 Case 2. (A) Corneal vascularisation and stromal scar following resection of a peribulbar dermoid. (B) Histology showing stratified squamous epithelium overlying a spindle cell lesion that embraces islands of adipose tissue and sweat gland elements. Magnification ×100.

At 18 months the right eye was found to be hypermetropic (+9.50) with associated exotropia (20 prism dioptres) (visual acuity was unobtainable) managed with a contact lens and intermittent patching of the left eye. Aged 3, he had 2/60 vision right, 6/5 left and a 5 dioptre exotropia. Contact lens wear was intermittent and by the age of 3 years, the right eye was +4.00DS with 2/60 vision.

COMMENT

The incidence of corneal vascularisation with epibulbar dermoids is low. It has been reported with ectopic lacrimal tissue choristoma, which may resemble pterygia.⁷ The majority are unilateral and lie on the temporal cornea. One third are associated with multiple colobomata.⁸ Henkind *et al* reported two cousins born of sisters with unrelated husbands, who presented with bilateral corneal choristomata.⁵ Histology demonstrated a thickened cornea covered by a keratinising stratified squamous epithelium containing hair tufts. Other abnormalities included absence of Bowman's layer and stromal invasion by a dense vascularised collagenous tissue. Penetrating keratoplasty led to early rejection and graft opacification, but in the contralateral eye a lamellar keratoplasty resulted in rapid visual rehabilitation with low astigmatism (as in our case).

Neither of our cases had lacrimal tissue within the biopsies taken indicating that other forms of limbal dermoid may be associated with or possibly induce stromal vascularisation.

Late referral for a specialist opinion occurred with both children. Early referral, especially in unilateral cases, is vital as lamellar keratoplasty and aggressive patching of the fellow eye could prevent amblyopia.

CL is grateful to Mr John Dart for helpful discussions regarding the management of case 1.

RICHARD NEWSOM
Sussex Eye Hospital, Brighton

WILLIAM AYLIFFE
SUSHMA DHAR-MUNSHI
Croydon Eye Unit, Mayday Hospital

NIGEL KIRKHAM
Royal Sussex County Hospital, Brighton

CHRISTOPHER LIU
Sussex Eye Hospital, Brighton

Correspondence to: Mr C Liu, Sussex Eye Hospital,
Eastern Road, Brighton BN2 5BF

Accepted for publication 12 July 1999

- 1 Spencer W, Zimmerman L. *Ophthalmic pathology: an atlas and textbook*. Philadelphia: WB Saunders, 1985.
- 2 Hutchinson DS, Green WR, Iliff CE. Ectopic brain tissue in a limbal dermoid associated with a scleral staphyloma. *Ophthalmology* 1973;76: 984-6.
- 3 Mattos J, Conteras F, O'Donnell Jr F. Ring dermoid syndrome. *Arch Ophthalmol* 1980;98: 1059-61.
- 4 Oakman JJ, Lambert S, Grossniklaus H. Discussion: Corneal dermoid: case report and review of classification. *J Pediatr Ophthalmol Strabismus* 1993;30:388-91.
- 5 Henkind P, Marinoff G, Manas A, et al. Bilateral corneal dermoids. *Am J Ophthalmol* 1973;76: 972-7.
- 6 Pokorny K, Hyman M, Jakobeic F, et al. Epibulbar choristomas containing lacrimal tissue. *Ophthalmology* 1987;94:1249-57.
- 7 Mann I. *Developmental abnormalities of the eye*. Philadelphia: Lippincott, 1957:357.
- 8 Topilow H, Cykiert R, Goldman K, et al. Bilateral corneal dermis like choristoma; an X chromosome-linked disorder. *Arch Ophthalmol* 1981;99:1387-91.

Herpes simplex virus (HSV-1) infection in a donor cornea

EDITOR,—According to polymerase chain reaction (PCR) studies¹ up to 20% of organ culture donor corneas may contain herpes simplex virus (HSV) DNA. Only five HSV donor cornea infections, however, have been reported worldwide¹⁻³ (J Garweg, M Böhnke, personal communication). In only one of the five cases published so far the infection was transmitted to the recipient.¹ The other four corneas showed severe endothelial damage and were discarded before transplantation.^{1,2} It is likely therefore that the whole virus must be present at the time of donor retrieval to result in subsequent transmission of disease to the recipient.⁴ We here report another donor cornea with HSV infection in organ culture.

CASE REPORT

The donor was a 74 year old woman with a history of severe ischaemic heart disease. After cardiac surgery she required ventilation for 3 weeks and finally died as a result of septicaemia. Screening serological tests performed 5 days before the donor's death revealed evidence of previous exposure to herpes simplex virus, varicella zoster virus, and cytomegalovirus infection without acute exacerbation. No conjunctival injection or corneal opacity was observed macroscopically. Both corneas were excised 2 hours post mortem and placed in organ culture 11 hours later. Slit lamp evaluation of the corneoscleral discs revealed epithelial dendritiform changes of the left cornea whereas the right cornea was clear (Fig 1). Endothelial cell count was estimated at 2500/mm² by phase contrast microscopy in both corneas. Seven days later total necrosis of the endothelium and the keratocytes was observed in the left cornea in contrast with only minor endothelial alterations of the right cornea. Routine bacteriological and mycological cultures at that time were negative, and the storage media were clear and normally coloured. A sample of each storage medium was cultured for virus and examined by PCR and

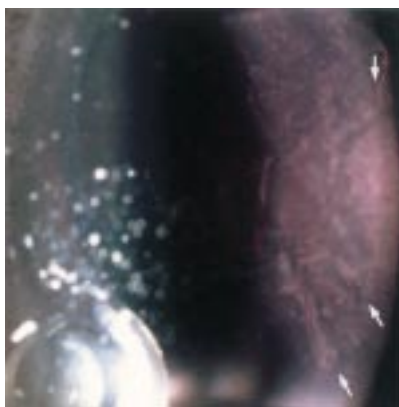


Figure 1 Epithelial dendritiform lesion on the graft in organ culture medium. View from the endothelial side of the corneoscleral disc.

the left cornea was fixed for microscopic examination. HSV-1 was detected by both methods in the medium of the left cornea but not of the right cornea. Histopathological examination confirmed unilateral total necrosis of the endothelium and the keratocytes. Immunohistochemical examination also gave an HSV-1 positive result. The right cornea was discarded 8 days later because of an insufficient endothelial cell count (below 2000).

COMMENT

This report illustrates for the first time in an organ culture cornea the course of an HSV-1 dendritic keratitis in the absence of immunological influence leading to complete necrosis of the endothelium and keratocytes. HSV-1 infection of the donor cornea was present already at the time of donor cornea excision supporting our hypothesis that horizontal transmission of HSV can only occur if active virus, and not only HSV-DNA fragments, is placed in organ culture. In addition to previously published reports we observed the typical clinical appearance of a dendritic corneal lesion in vitro. This provides compelling further evidence for HSV-1 infection of donor cornea as a cause for subsequent endothelial cell loss in organ culture.

U SENGLER
H SPELSBERG
T REINHARD
R SUNDMACHER

Eye Hospital, Heinrich-Heine-University,
Düsseldorf, Germany

O ADAMS
Medical Microbiology and Virology,
Heinrich-Heine-University, Düsseldorf, Germany

C AUW-HAEDRICH
H WITSCHHEL
Eye Hospital, Albert-Ludwigs-University,
Freiburg, Germany

Correspondence to: U Sengler, MD, Eye Hospital,
Heinrich-Heine-University, Moorenstrasse 5,
D-40225 Düsseldorf, Germany

Accepted for publication 28 July 1999

- 1 Cleator GM, Klapper PE, Dennett C, et al. Corneal donor infection by herpes simplex virus: herpes simplex virus DNA in donor corneas. *Cornea* 1994;31:294-304.
- 2 Tullo AB, Marcyniuk B, Bonshek R, et al. Herpes virus in a corneal donor. *Eye* 1990;4:766-7.
- 3 O'Day DM. Diseases potentially transmitted through corneal transplantation. *Ophthalmology* 1989;96:1133-8.
- 4 Morris DJ, Cleator GM, Klapper PE, et al. Detection of herpes simplex virus DNA in donor cornea culture medium by polymerase chain reaction. *Br J Ophthalmol* 1996;80:54-65.

A case of acquired iris depigmentation as a possible complication of levobunolol eye drops

EDITOR,—Changes in iris pigmentation occur in relation to many circumstances, the most topical of which probably is iris hyperpigmentation associated with the prostaglandin analogue latanoprost. We report on a case of bilateral iris depigmentation with levobunolol eye drops and we suggest that changes in local iris prostaglandin concentrations may be responsible.

CASE REPORT

We report on the case of a 68 year old man who, after 5 years of using exclusively levobunolol eye drops twice daily to both eyes, reported that the colour of both of his eyes was changing from brown to blue.

The drops were started 5 years ago for raised intraocular pressure when his intraocular pressures were found to be 32 mm Hg in each eye after a 5 year period of monitoring of ocular hypertension. Although there was no satisfactory photographic evidence of his eyes being brown previously, his service record stated that they once were.

Recent examination revealed that the stroma was indeed mostly depigmented with only a central area of brown pigmented stroma overlying the central ciliary area and a few small iris naevi in each eye (Fig 1A and B). Neither iris was atrophic. There were no transillumination defects and no pigment was deposited on the lens, cornea, or iridocorneal angle in either eye. There were no other signs suggestive of Horner's syndrome and both anterior segments were quiet with no keratic precipitates. Both fundi appeared normal, except for cupped optic discs with cup to disc ratios of 0.8 right and left.

COMMENT

Iris colour depends on melanosomes present within the melanocytic cells of the anterior border and melanocytes of the iris stroma, as well as on the thickness of the iris stroma. Variation in the pigmentation of the iris pigment epithelium is not thought to play an important role.¹

Heterochromia has been widely described with congenital Horner's syndrome especially after forceps delivery and heterochromia has also been reported in longstanding acquired Horner's syndrome in humans.² The effects of iris depigmentation following cervical sympathectomy in rabbits and rodents has been described in 1919 by Calhoun.³ The peripheral stroma is generally depigmented reflecting the distribution of sympathetic neurons in the above situations.

Levobunolol is a non-selective blocker of both β_1 and β_2 receptors and is considered to be similar in its effects to timolol. It is tempting to speculate that 5 years of a pharmacologically induced state of Horner's syndrome with the use of levobunolol eye drops has led to depigmentation of the irides in this case. Iris naevi appear not to be affected by congenital Horner's syndrome appearing equally dark, as in our case, in affected and unaffected eyes.^{4,5} To the best of our knowledge, there has been no previous report of iris heterochromia following the use of timolol or levobunolol eye drops.

There has been recent interest in increased iris pigmentation following the use of latanoprost eye drops. Its side effect is increased melanosome synthesis without effects on

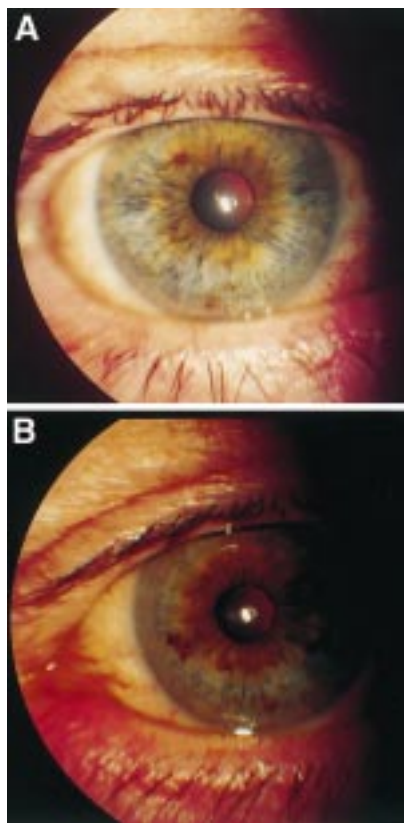


Figure 1 (A) Macrophotograph of right eye. (B) Macrophotograph of left eye.

melanocyte cell counts.^{6,7} It is possible that prostaglandin induced iris pigmentation may be the final pathway of the maintenance of iris pigmentation by endogenous catecholamines. Latanoprost has been shown to abolish sympathetomy induced iris hypopigmentation in rabbits.⁸ Relatively low catecholamine levels may result in low prostaglandin levels and hence hypopigmentation, an effect which may be reversed by administration of latanoprost eye drops. Prostaglandins are also thought to mediate the lowering of intraocular pressure at 22–24 hours after surgical sympathetomy in rabbits.⁹

Further clinical and laboratory studies into the long term effects of topical adrenergic agents on iris pigmentation may confirm whether our isolated case of iris hypopigmentation is of significance and may provide insight into the relation between catecholamines and prostaglandins and their ocular effects.

EDDIE DOYLE
CHRISTOPHER LIU

Sussex Eye Hospital, Brighton BN2 5BF

Correspondence to: Mr C S C Liu, Sussex Eye Hospital, Brighton BN2 5BF

Accepted for publication 11 August 1999

- 1 Miller D. Eye colour. *Duane's ophthalmology*. Volume 1, Chapter 31. Philadelphia: Lippincott-Raven, 1997.
- 2 Diesenhouse MC, Palay DA, Newman NJ, et al. Acquired heterochromia with Horner syndrome in two adults. *Ophthalmology* 1992;99:1815–17.
- 3 Calhoun FP. Causes of heterochromia iridis with special reference to paralysis of the cervical sympathetic. *Am J Ophthalmol* 1919;2:255–69.
- 4 Dryja TP, Albert DM. Lack of adrenergic influence on the pigment of iris naevus cells. *Arch Ophthalmol* 1980;98:1996–7.
- 5 McCartney ACE, Riordan-Eva P, Howes RC, et al. Horner's syndrome: an electron microscopic study of a human iris. *Br J Ophthalmol* 1992;76:746–9.

- 6 Wistrand PJ, Stjernschantz J, Olsson K. The incidence and time-course of latanoprost-induced iridial pigmentation as a function of eye colour. *Surv Ophthalmol* 1997;41(Suppl 2):S129–38.
- 7 Selen G, Stjernschantz J, Resul B. Prostaglandin induced iridial pigmentation in primates. *Surv Ophthalmol* 1997;41(Suppl 2):S125–8.
- 8 Zahn G, Toris CB, Camras CB, et al. Prostaglandin-induced iris colour darkening. *Arch Ophthalmol* 1998;116:1065–8.
- 9 Camras CB, Zahn GL, Ohia S, et al. The role of prostaglandins and neuropeptide Y in the reduction of intraocular pressure 1 day after sympathetomy in rabbits. *Invest Ophthalmol Vis Sci* 1993;34(suppl):932.

Horner's syndrome in yolk sac tumour of the mediastinum

EDITOR,—Primary yolk sac tumour of the mediastinum is a rare germ cell tumour. Sporadic case reports document the presenting features of chest pain, cough, shortness of breath, and superior vena cava syndrome. To our knowledge, this is the first case to present with Horner's syndrome.

CASE REPORT

A 23 year old man was referred with anisocoria. For 3 months the left pupil had been noted to be smaller than the right although the patient reported it enlarged significantly after he took amphetamine tablets. Medical history was unremarkable apart from the recent onset of hip and shoulder pain for which he had been referred to a rheumatologist.

Examination revealed a mild left ptosis in addition to the anisocoria and a diagnosis of Horner's syndrome was made. The history of pupillary dilatation following ingestion of amphetamine tablets indicated a preganglionic lesion and closer questioning elicited the presence of a mass on the left anterior chest wall which had been enlarging painlessly over the preceding 5 months. There were no associated chest symptoms.

A subsequent computed tomograph (CT) scan demonstrated a mass over the left second rib (Fig 1), bilateral adrenal masses, extensive liver metastases, and enlarged supraclavicular nodes around the sympathetic chain. Biopsy of the right adrenal mass showed tumour composed of cells arranged predominantly in glandular formations. The tumour cells showed positive immunohistochemical staining for α fetoprotein, carcinoembryonic antigen, and cytokeratin (CAM), consistent with a diagnosis of metastatic germ cell tumour containing yolk sac elements. This diagnosis was supported by a grossly elevated serum α fetoprotein of 29 340 (N <10 ng/ml) ng/ml and normal serum β human chorionic gonadotrophin. The patient therefore underwent combination chemotherapy (bleomycin, etoposide, cisplatin) directed at a germ cell aetiology.

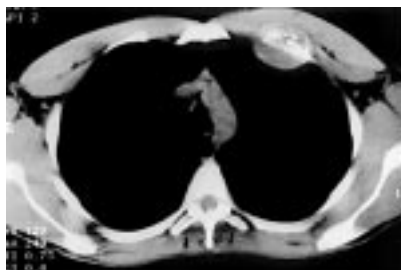


Figure 1 Computed tomographic scan of the chest showing a mass in the left anterior chest wall.

COMMENT

Yolk sac tumour of the anterior mediastinum is a rare highly malignant tumour believed to arise from germ cells arrested during migration.¹ Most patients are young men, the majority presenting with non-specific chest symptoms.² Serum α fetoprotein is nearly always markedly elevated,³ with histological examination showing characteristic Schiller-Duval bodies. Early diagnosis provides the best chance of prolonging survival. Many have extensive spread however and prognosis in advanced cases remains poor in spite of modern chemotherapy.

The presence of an isolated preganglionic Horner's syndrome in any patient necessitates radiological investigation of the pulmonary apex and chest. Pain in the shoulder or arm, as in this case, is typical of lesions in this area.

CAROLYN A CATES
DAVID E ETCHELLS
E DAVID DORRELL

Department of Ophthalmology, Royal Victoria Eye Hospital, Westbourne, Bournemouth

KUDAIR HUSSEIN

Department of Pathology, Poole Hospital, Poole

Correspondence to: Mrs Carolyn Cates

Accepted for publication 11 August 1999

- 1 Teilmann I, Kassis H, Pietra G. Primary germ cell tumor of the anterior mediastinum with features of endodermal sinus tumor (mesoblastoma vitellinum). *Acta Pathol Microbiol Scand* 1967;70:267–78.
- 2 Truong L, Harris L, Mattioli C, et al. Endodermal sinus tumor of the mediastinum. Report of seven cases and review of the literature. *Cancer* 1986;58:730–9.
- 3 Talerma A, Haije WG, Baggerman L. Serum alpha-fetoprotein (AFP) in patients with germ cell tumors of the gonads and extragonadal sites. *Cancer* 1980;46:380–5.

Phacoemulsification combined with silicone oil removal through posterior capsulorhexis

EDITOR,—Silicone oil is useful in the treatment of some cases of retinal detachment with severe proliferative vitreoretinopathy.¹ With prolonged silicone lens contact, a permanent cataract will form in all cases.^{2,3} In order to reduce the incidence of postoperative complications in silicone filled eyes, many authors recommend that silicone oil should be removed from the eye as soon as a stable retinal situation is achieved.^{1,2,4,6}

We performed phacoemulsification and silicone oil removal through a planned posterior capsulorhexis.

CASE REPORTS

The retrospective study included 10 patients with proliferative vitreoretinopathy, seven females and three males, ranging in age from 12 to 82 years. Pars plana vitrectomy, membrane peeling, encircling band, and silicone oil tamponade were performed 6 months before removal of the silicone oil. The mean refractive error was –2.50 dioptres (range –10 to 0.50 dioptres).

Conventional phacoemulsification was performed and a central posterior capsulorhexis was performed using the capsulorhexis forceps. Silicone oil was removed through the posterior capsulorhexis with the irrigation-aspiration handpiece and the corneal incision was not widened. In eight patients soft acrylic foldable lenses were implanted in the capsular bag. Two patients received a heparin modified poly(methylmethacrylate) lens, one into the capsular bag and one in the sulcus.

The preoperative intraocular lens (IOL) power calculation was performed with the modified SRKII formula, using the axial length of the fellow eye.

The mean follow up period after cataract surgery was 7.5 months. Prolapse of the iris and loss of the iris pigment epithelium did not occur during surgery. One posterior capsular rupture occurred during hydrodissection.

Two cases of transient postoperative corneal oedema were noted. One of the patients had recurrence of his retinal detachment 1 month after silicone oil removal. This patient underwent successful reattachment after silicone oil endotamponade.

The visual acuity improved in nine of the 10 eyes. Nine eyes achieved a best corrected visual acuity of 0.4 or better.

The postoperative refraction was more myopic than predicted by an average of 1.7 dioptres.

COMMENT

Silicone oil can cause anterior segment complications.¹⁻⁴ There is evidence that these complications can be prevented by its early removal.^{2,6} Removal of silicone oil combined with cataract extraction reduces the number of surgical procedures.

After silicone oil removal the eyes were hypotonic during surgery. Foldable IOLs were implanted in eight eyes to reduce postoperative astigmatism. Silicone oil was observed to be adherent to the silicone IOL surface,⁸ for this reason we prefer implantation with the Acrysof IOL (Alcon).

Unpredictable refraction in eyes filled with silicone oil is the main problem. The use of specific sound velocities to calculate axial length has been proposed.⁹

Jonas and coworkers first reported cataract surgery combined with transpupillary silicone oil removal through planned posterior capsulotomy.¹⁰ They removed the silicone oil by an essentially passive technique. The main difficulty of this technique was the prolapse of the iris. In our technique there was no widening of the corneal incision and iris prolapse did not occur. This technique avoided contamination of the operative field with the silicone oil. This method did not permit additional membrane peeling or retinal stabilisation and must be reserved for cases of stable retina with no or few recurrent membranes and closed retinal breaks.

E FRAU

Department of Ophthalmology, Hospital of Bicêtre,
France, University Paris XI, France

M LAUTIER-FRAU

Department of Ophthalmology, Pitié-Salpêtrière
Hospital, Paris, France

M LABÉTOULLE

S HUTCHINSON

H OFFRET

Department of Ophthalmology, Hospital of Bicêtre,
France, University Paris XI, France

Correspondence to:

Dr E Frau

Accepted for publication 28 July 1999

1 McCuen BW, Landers MB, Machemer R. The use of silicone oil following failed vitrectomy for retinal detachment with advanced proliferative vitreoretinopathy. *Ophthalmology* 1985;92:1029-34.

2 Casswell AG, Gregor ZJ. Silicone oil removal. I. The effect on the complications of silicone oil. *Br J Ophthalmol* 1987;71:893-7.

3 Franks WA, Leaver PK. Removal of silicone oil—rewards and penalties. *Eye* 1991;5:333-7.

4 McCuen BW II, De Juan E, Landers MB, et al. Silicone oil in vitreoretinal surgery. II. Results and complications. *Retina* 1985;5:198.

5 Zilis JD, McCuen BW II, de Juan E Jr, et al. Results of silicone oil removal in advanced proliferative vitreoretinopathy. *Am J Ophthalmol* 1989;108:15-21.

6 Hutton WL, Azen SP, Blumenkranz MS, et al. The effects of silicone oil removal. Silicone Study Report 6. *Arch Ophthalmol* 1994;112:778-85.

7 Sternberg PJ, Hatchell DL, Foulks GN, et al. The effect of silicone oil on the cornea. *Arch Ophthalmol* 1985;103:90-4.

8 Senn P, Schmid MK, Schipper I, et al. Interaction between silicone oil and silicone intraocular lenses: an in vitro study. *Ophthalmic Surg Laser* 1997;28:776-9.

9 Meldrum ML, Aaberg TM, Patel A, et al. Cataract extraction after silicone oil repair of retinal detachments due to necrotizing retinitis. *Arch Ophthalmol* 1996;114:885-92.

10 Jonas JB, Budde WM, Panda-Jonas S. Cataract surgery combined with silicone oil removal through planned posterior capsulotomy. *Ophthalmology* 1998;105:1234-8.

Modified Sheridan-Gardiner vision test with a semitransparent card

EDITOR,—Testing visual acuity in children can be difficult, largely because of their lack of knowledge of the alphabet. Their short attention span and poor cooperation also contribute.

The Sheridan-Gardiner method is a very useful and widely used for testing vision in children, especially preschool children and those with learning difficulty.

The examiner shows letters of different sizes (corresponding to different levels of Snellen acuity) from a distance of 6 metres, to a child who holds a card with the same letters. Older children will point to the letter and turn the card to show it to the examiner. In most instances, however, the help of a second person is needed. This person indicates to the examiner whether or not the child has pointed to the correct letter.

In our modification of the Sheridan-Gardiner test, the child is given a semitransparent card with a tinge of pink colour. The letters are in black and can easily be seen against the pink background. This enables the

examiner to directly visualise the letters pointed to by the child obviating the need of a second person (Fig 1).

The modified card was validated by comparing the results of visual acuity testing in 30 children (5-7 years old) each, by two school nurses. One nurse held the test cards at 6 metres and the other sat beside the child. The conventional method was first used and vision recorded. The modified card was then given to the child and the test repeated. In another group of 30 children, the nurses reversed roles and again both the conventional and modified cards were used.

With the conventional method only three out of 30 in one group and four out of 30 in the other group could be tested without the second person's help. With the modified card, all children in each group could be tested easily and quickly without the second person's help.

In our opinion, use of the modified semitransparent card will improve the efficiency of testing vision in children.

RIYAZ AHMED

Division of Ophthalmology and Vision Sciences,
University of Nottingham and the Department of
Ophthalmology, District General Hospital, Rotherham

H S DUA

Department of Ophthalmology, District General
Hospital, Rotherham

Correspondence to: Dr Ahmed

Accepted for publication 11 August 1999

Corneal fleck dystrophy in an English family

EDITOR,—Fleck corneal dystrophy is a rare, stable, and usually asymptomatic condition. It is characterised by numerous small white flecks scattered in all layers of the stroma from the centre to the periphery. François and Neetens described the condition for the first time in 1957¹ and called it "hérérodystrophie mouchetée" while Streeten and Falls reported two families with the same condition in 1961² and translated the name to hereditary fleck dystrophy of the cornea. Only a few families have been reported in the literature and the dystrophy is thought to be rare, not well recognised, and easily missed by the ophthalmologist. We report on three affected members of an English family and comment on the differences with other described cases.

CASE REPORT

A 65 year old white man with no ocular history attended the eye casualty department for the treatment of a small right traumatic corneal abrasion. His best corrected visual acuities were 6/5 on the right and 6/6 on the left. Slit lamp examination revealed numerous bilateral small grey-white fleck-like opacities scattered in his corneal stroma at all levels,



Figure 1 Use of the modified semitransparent Sheridan-Gardiner chart. It is easy for the examiner to observe the letter pointed at by the child.

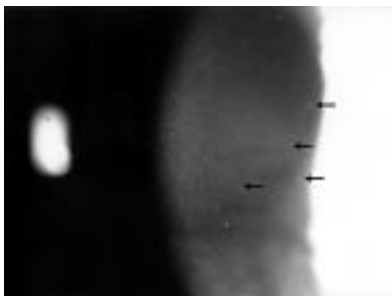


Figure 1 Flecks (arrows) scattered in the corneal stroma at all levels.

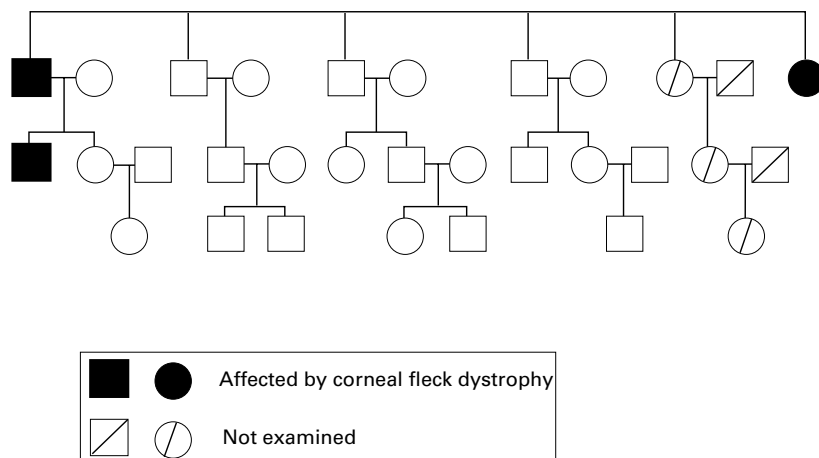


Figure 2 Pedigree of the English family with corneal fleck dystrophy.

with variable density and affecting both the central and peripheral cornea (Fig 1). There was clear intervening stroma between the lesions and associated anterior crocodile shagreen bilaterally. His epithelium and endothelium appeared normal and his corneal sensation was reduced.

Other members in three generations of his family were examined. The patient's son and one sister also had corneal fleck dystrophy bilaterally as shown in the family pedigree (Fig 2).

The affected members were asymptomatic and had normal vision. The lesions were identical and followed a similar distribution in all three patients with a lesser density in the patient's sister who also had decreased corneal sensation and associated anterior crocodile shagreen. On the other hand the patient's son had prominent corneal nerves but normal corneal sensation. There were no other associated ocular or systemic abnormalities.

COMMENT

This is the first English family with corneal fleck dystrophy reported in the literature. Since the original description by François and Neetens¹ there have been a number of reports establishing the dominant inheritance and the variable expressivity of this benign condition.²⁻⁴ Only one family reported by Gillespie and Covelli⁵ showed autosomal

recessive inheritance with no apparent difference in phenotypic expression. According to the original description, the subtle, round, oval, or wreath-like lesions have sharp borders and vary in size and number. All levels of the stroma are affected with the lesions extending to the limbus.¹ Asymmetrical involvement of the two eyes is common and unilateral involvement has been noted.^{2,5,6} Patients are usually asymptomatic and a very few report occasional photophobia.⁷

The pathogenesis of this dystrophy remains obscure. Impaired or deficient hydrolytic enzymes within the keratocytes might be responsible for the abnormal accumulation of intracellular mucopolysaccharide and lipid.⁸⁻¹⁰ Extensive investigations failed to detect an underlying systemic metabolic abnormality⁷ and this condition might represent a localised storage disorder limited to the cornea and confined to the keratocytes.

While our cases of hereditary fleck dystrophy are similar to those previously reported, the only notable difference is the presence of associated anterior crocodile shagreen in two patients and prominent corneal nerves in another. Because anterior crocodile shagreen is usually bilateral and seen in the elderly, its association with fleck dystrophy in two patients is likely to be a concurrent event due to chance only. On the other hand a familial and dystrophic form of posterior crocodile sha-

green has been described as central cloudy dystrophy by François¹¹ and found to be associated to fleck dystrophy in the same patient¹² and in different members of the same family.^{1,5} Decreased corneal sensation initially reported by Bindorf and Ginsberg in 1972⁶ is only present in two of our patients. This variable association has also been confirmed in other reports.^{2,4,8}

The importance of fleck dystrophy lies in its recognition as a non-progressive and benign condition compared with other inherited but progressive stromal dystrophies. The diagnosis should not be difficult in most cases. Its asymptomatic nature together with the distinctive forms and distribution of the stromal opacities can differentiate it easily from other known dystrophies such as Groenouw's granular dystrophy.

A ASSI
N EBENEZER
L FICKER

Moorfields Eye Hospital, City Road, London EC1 2PV

Correspondence to: Mr A Assi

Accepted for publication 23 August 1999

- 1 François JMM, Neetens A. Nouvelle dystrophie hérédofamiliale du parenchyme cornéen (Hérédodystrophie mouchetée). *Bull Soc Belge Ophthalmol* 1957;114:641-5.
- 2 Streeten BW, Falls HF. Hereditary fleck dystrophy of the cornea. *Am J Ophthalmol* 1961;51:275-8.
- 3 Aracena T. Hereditary fleck dystrophy of the cornea: report of a family. *J Pediatr Ophthalmol* 1975;12:223-7.
- 4 Goldberg MF, Krimmer B, Sugar J, et al. Variable expression in flecked (speckled) dystrophy of the cornea. *Ann Ophthalmol* 1977;9:889-96.
- 5 Gillespie F, Covelli B. Fleck (mouchetée) dystrophy of the cornea. *South Med J* 1963;56:1265-7.
- 6 Bindorf LA, Ginsberg SP. Hereditary fleck dystrophy associated with decreased corneal sensitivity. *Am J Ophthalmol* 1972;73:670-2.
- 7 Patten JT, Hyndiuk RA, Donaldson DD, et al. Fleck (mouchetée) dystrophy of the cornea. *Ann Ophthalmol* 1976;8:25-32.
- 8 Purcell JP, Krachmer JH, Weingeist TA. Fleck corneal dystrophy. *Arch Ophthalmol* 1977;95:440-4.
- 9 Nicholson DH, Green WR, Cross HE, et al. A clinical and histopathological study of François-Neetens speckled corneal dystrophy. *Am J Ophthalmol* 1977;83:554-60.
- 10 Kiskaddon BM, Campbell RJ, Waller RR, et al. Fleck dystrophy of the cornea: case report. *Ann Ophthalmol* 1980;12:700-4.
- 11 François J. Une nouvelle dystrophie hérédofamiliale de la cornée. *J Génét Hum* 1956;5:189.
- 12 Collier MM. Dystrophie nuageuse centrale et dystrophie ponctiforme prédescémétrique dans une même famille. *Bull Soc Ophthalmol* 1966;66:575-9.