

Published in final edited form as:

*Obstet Gynecol.* 2006 May ; 107(5): 1064–1069.

## Appearance of the Levator Ani Muscle Subdivisions in Magnetic Resonance Images

Rebecca U. Margulies, Md, Yvonne Hsu, Md, Rohna Kearney, Mrcog, Tamara Stein, PhD, Wolfgang H. Umek, Md, and John O. L. DeLancey, Md

From the University of Michigan, Ann Arbor, Michigan; University College Hospital, London, United Kingdom; and Medical University Vienna, Vienna, Austria.

### Abstract

**OBJECTIVE**—Identify and describe the separate appearance of 5 levator ani muscle subdivisions seen in axial, coronal, and sagittal magnetic resonance imaging (MRI) scan planes.

**METHODS**—Magnetic resonance scans of 80 nulliparous women with normal pelvic support were evaluated. Characteristic features of each Terminologia Anatomica–listed levator ani component were determined for each scan plane. Muscle component visibility was based on pre-established criteria in axial, coronal, and sagittal scan planes: 1) clear and consistently visible separation or 2) different origin or insertion. Visibility of each of the levator ani subdivisions in each scan plane was assessed in 25 nulliparous women.

**RESULTS**—In the axial plane, the puborectal muscle can be seen lateral to the pubovisceral muscle and decussating dorsal to the rectum. The course of the puboperineal muscle near the perineal body is visualized in the axial plane. The coronal view is perpendicular to the fiber direction of the puborectal and pubovisceral muscles and shows them as “clusters” of muscle on either side of the vagina. The sagittal plane consistently demonstrates the puborectal muscle passing dorsal to the rectum to form a sling that can consistently be seen as a “bump.” This plane is also parallel to the pubovisceral muscle fiber direction and shows the puboperineal muscle.

**CONCLUSION**—The subdivisions of the levator ani muscle are visible in MRI scans, each with distinct morphology and characteristic features.

### LEVEL OF EVIDENCE: III

Pelvic organ prolapse is a major public health problem, with over 200,000 inpatient surgical procedures performed annually in the United States to treat this condition.<sup>1</sup> Damage to the levator ani muscles has been implicated for a century as a cause of pelvic organ prolapse.<sup>2–4</sup> Recent advances in magnetic resonance imaging (MRI) have allowed us to study the appearance of these muscles in normal women<sup>6,5</sup> and in women with pelvic floor dysfunction.<sup>7,8</sup>

The levator ani complex comprises 5 distinct origin-insertion pairs or subdivisions,<sup>9,10</sup> each with its own unique mechanical effect. The consequence of levator ani muscle damage might depend on which or how many elements have been damaged. For example, one might hypothesize that a damaged pubovaginal attachment could result in cystocele formation, whereas puborectal damage might cause a rectocele. The ability to identify each muscle subdivision is necessary to correlate defects in specific origin-insertion pairs with matching

Corresponding author: Rebecca U. Margulies, MD, Department of Obstetrics & Gynecology, L4000 Women's Hospital, 1500 E. Medical Center Drive, Ann Arbor, MI 48109-0276; e-mail: rmarguli@med.umich.edu..

This study was supported by the National Institutes of Health through the Office for Research on Women's Health SCOR on Sex and Gender Factors Affecting Women's Health, NICHD P50 HD 44406 and R01 HD 38665.

clinical findings. Correlation of specific subdivision disruptions with clinical findings might allow surgeons to tailor diagnosis and treatment to a particular individual. Visible distinctions in the levator ani subdivisions exist in MRI scans of the muscle. Until the subdivisions of the levator ani muscle can be objectively demonstrated in MRI scans, it is not possible to test hypotheses concerning the relationship between a specific muscle injury and specific type of prolapse. The purpose of this study is to examine the MRI appearance of the 5 individual subdivisions of the levator ani muscle in nulliparous women with normal pelvic organ support.

## MATERIALS AND METHODS

There were 3 phases to this study. The purpose of the first phase was to gain familiarity with the anatomy of the levator subdivisions and to determine characteristic features for each subdivision in each scan plane. In the first phase, a sample of 80 MRI scans of nulliparous, continent, asymptomatic women with normal pelvic support was evaluated to gain experience with the morphological appearance of the muscle subdivisions using previously published anatomical information.<sup>10</sup> Women were asymptomatic volunteers in 2 ongoing institutional review board (IRB)-approved case-control studies investigating pelvic organ prolapse and urinary incontinence. The patients were recruited through newspaper advertisements, fliers, and the Women's Health Registry, a local database of women interested in participating in women's health research. The mean age of these subjects was 29.2 years (standard deviation [SD] 5.5), mean body mass index (BMI) was 24.4 (SD 4.4), 92% were white, 3% were African American, and 5% were classified as "other." Race was determined by self-identification.

Magnetic resonance imaging scans were obtained by using a previously described protocol.<sup>11</sup> Proton density T-2 weighted scans and 2-dimensional (2D) fast-spin proton density MRI scans were performed at 5-mm intervals in the axial, sagittal, and coronal planes in the supine position with a 1.5 Tesla super-conducting magnet (Signa; General Electric Medical Systems, Milwaukee, WI). The senior author and at least one other author reviewed each scan. The investigators then discussed the morphology of the subdivisions and arrived at a consensus on the characteristic features. The characteristic features of each of the 5 separate levator subdivisions were determined for each scan plane by the following 2 criteria: 1) a clear and consistently visible separation between a structure and adjacent structures, or 2) differing origin or insertion of the muscle. These characteristic features are summarized in Table 1.

In the second study phase, an exemplary scan of a 25-year-old nulliparous woman was selected for image clarity and the 3 scan planes were imported into 3D Slicer 2.1b1 (MIT Artificial Intelligence Laboratory at Brigham and Women's Hospital, Boston, MA). This program permitted the appearance of muscles in one scan plane (eg, axial) to be compared with the appearance of the same muscle in other planes (eg, sagittal or coronal) by displaying the images from each orthogonal plane in the same 3D space. Next, a 3D model of the levator ani subdivisions was created (Fig. 1) by tracing each of the subdivisions in the orthogonal planes. The creation of this model was necessary both for understanding and for displaying the MRI characteristic features as well as the 3D orientation of the subdivisions.

In the third phase, 25 MRI scans were selected for image quality from a separate ongoing IRB-approved study of healthy nulliparous women designed to investigate the effects of age on pelvic floor function. This phase of the study was designed to evaluate the visibility of the characteristic features determined in the first phase of the study. These subjects had a mean age of 26.4 years (SD 2.7) and mean BMI of 24.5 (SD 3.7); 92% were white, and 8% were Asian or Pacific Islanders, by self-identification. The levator ani muscles in these scans were examined for the visibility of the subdivisions according to the 2 criteria noted above. For each subject, muscle subdivisions were scored as "visible" or "not visible" in the axial, coronal, and sagittal scan planes. The visibility was scored by 2 independent investigators (R.M. and T.S.)

who were blinded to the results of the other observer. Interrater reliability was calculated by taking the number of agreements and dividing by 25, the total number of subjects.

## RESULTS

Figure 1 shows the 3D model of the 5 subdivisions of the levator ani muscle for orientation. The puboanal, puboperineal, and pubovaginal muscles form a single mass in some regions and are separately classified because of their different insertion points. They are, therefore, displayed together as a single structure for visual clarity. (We have chosen to use the term *pubovisceral* rather than *pubococcygeal* for this muscle because the former term is more anatomically descriptive.<sup>10</sup>) The model also displays the puborectal and the iliococcygeal muscles. This model provides a topographical overview to aid in the interpretation of Figures 2, 3, and 4, which depict the MRI cross-sectional anatomy of the subdivisions in the axial, coronal, and sagittal scan planes.

The axial plane provides a clear view of the pubovisceral muscle and its subdivisions (Fig. 2). The puboanal, puboperineal, and pubovaginal muscles can be seen to originate together from the inner surface of the pubic bone (eg, panels 0.0, +0.5) and course medial to the puborectal muscle in proximity to the vagina. Near the pubic origin, the pubovisceral subdivisions cannot be distinguished. However, the different insertion points can be seen. The medial pubovaginal attachment to the right vaginal wall is seen in panel 0.0. The puboanal portion can be seen passing into the intersphincteric space (eg, panel +1.0). The puboperineal muscle can be seen entering into the perineal body (eg, panels -2.0, -2.5).

The puborectal muscle is a subdivision that can be distinguished from the 3 elements of the pubovisceral muscle. It originates lateral to the pubovisceral muscle and appears as a sling dorsal to the rectum (eg, panels +2.5 to +1.0). Note that both the puborectal and puboperineal muscles have fiber directions that are oblique to the axial scan plane, such that the entire muscle loop is not visible in any one slice. The iliococcygeal muscle arises from the arcus tendineus levator ani that overlies the obturator internus (eg, panel +2.5, +2.0). In more cranial slices, it can be seen passing around the rectum above the fibers of the puborectal muscle.

Figure 3 shows the coronal plane in which the pubovisceral muscle lies perpendicular to the scan plane (Fig. 3). The pubovaginal attachment is again identified as medial fusion of the muscle with the vaginal wall (eg, panel -2.0). It is difficult to distinguish between the pubovisceral and the puborectal muscles in this orientation (eg, panels -1.5 to -4.0) because their fibers are contiguous and without visible separation; the two together are seen as a single body of muscle lateral to the vagina. Similarly, the subdivisions composing the pubovisceral muscle cannot be separated in the coronal MRI cross-sections. The coronal plane is optimal for viewing the iliococcygeus in the dorsal parts of the pelvis (eg, panels -4.0 to -7.0). This winglike configuration is visible as it arises from its lateral attachments to the arcus tendineus levator ani over the obturator internus muscle.

The sagittal plane (Fig. 4) offers the distinct advantage of being parallel to the pubovisceral and puborectal muscle fiber directions, allowing the fiber direction to be seen. There is a clear view of the puboperineal portion, just cephalad to the perineal membrane (eg, panels R1.5 to R0.5; this notation indicates the number of centimeters to the right of the midsagittal plane). The puboanal fibers can be seen as they course to the upper level of the external anal sphincter (eg, panels R2.0, R1.5), but the pubovaginal attachment cannot be seen in this orientation. The fibers of the puborectal muscle are visible as they pass dorsal to the rectum with decussating fibers forming a “bump” that is consistently visible. The sagittal images show the shelflike orientation of the iliococcygeus muscle (eg, panels R2.5 to R1.0), which has been referred to as the “levator plate” by various authors.<sup>4,12</sup>

## DISCUSSION

Using specific criteria for visual identification (visible separation or differing origin-insertion of the muscle), we have been able to separate 5 subdivisions of the levator ani muscle in living women on MRI scans. Injury to each component might be expected to have a different functional effect. This study identifies the unique advantages of each scan plane to depict the complex structure of the levator ani. We found the axial MRI cross-sections, as well as characteristic features such as the puborectal “bump” in the sagittal plane, to be particularly useful in distinguishing between different subdivisions. In addition, the ability to place orthogonal scans in the same 3D space was invaluable, both for identifying anatomic structures and for understanding the complex spatial arrangements of the subdivisions.

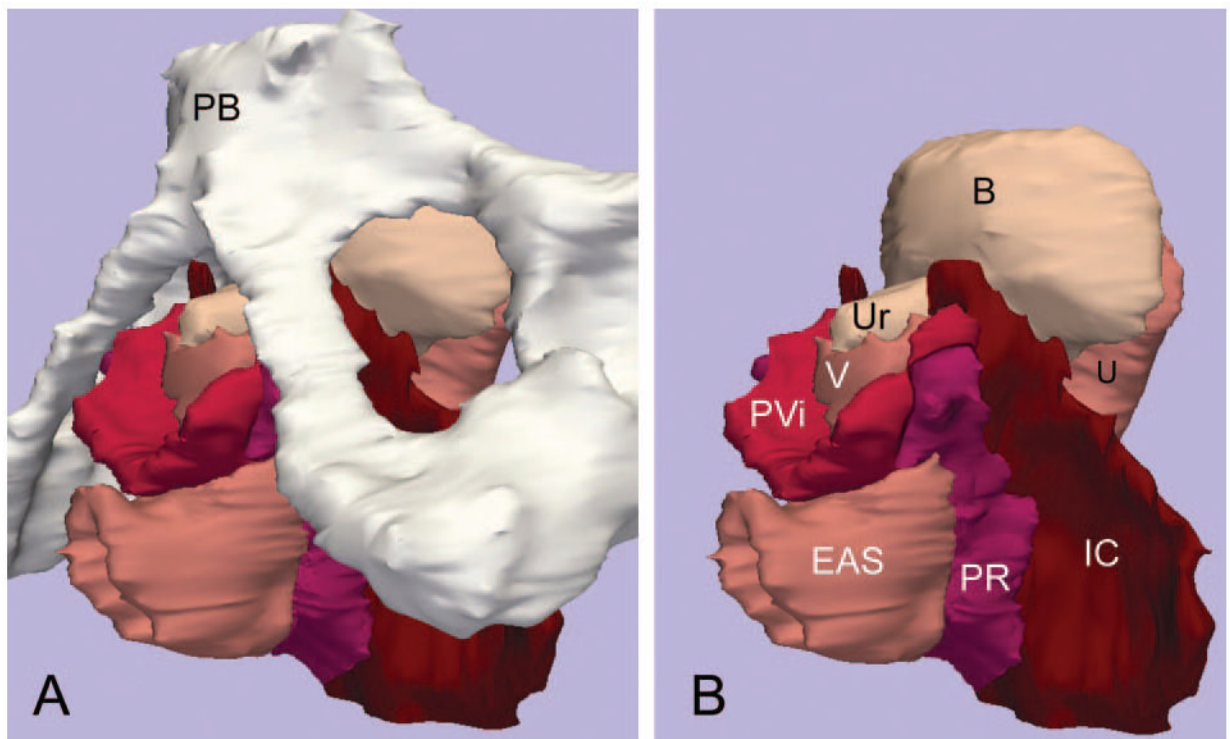
A thorough anatomic analysis lays the foundation necessary for understanding the specific mechanical etiologies of pelvic floor disorders. Each component of the levator ani muscle has a unique origin-insertion pair, and thus, a unique line of action. An injury to each individual subdivision of the levator ani would be expected to have a specific functional effect resulting in a unique deficit. For example, the puboanal muscle connects the anus to the pubis. If this muscle were damaged, the elevation of the anus could be lost and the genital hiatus widened. The puborectal muscle forms a sling around the rectum, thereby supporting the angle between the anus and rectum but does not elevate the anus. Disruptions to the puboanal or puborectal muscles would be expected to result in different patterns of pelvic floor dysfunction. Now that the subdivisions of the levator ani muscle have been clearly established in normal individuals, we can move forward to understand the correlation between specific anatomic defects and the varieties of pelvic floor dysfunction. Future research will focus on comparing defects in the individual subdivisions of women with and those without prolapse.

Although we have demonstrated that sufficient clarity exists on MRI images to distinguish the subdivisions of the levator ani muscle, limitations exist in using MRI studies to investigate muscle anatomy. Magnetic resonance imaging scan quality has not yet been refined to the point of allowing division of fiber bundles running in the same direction as in the case of the pubic origin of the subdivisions that make up the pubovisceral muscle. Because the levators have a complicated 3D geometry, it is not possible to use any one orthogonal scan plane to distinguish the subdivisions. Using the unique features from multiple planes overcomes this problem in many areas. In this study of women with normal support, we found that 2 independent examiners could consistently identify the visibility of the subdivisions. It should therefore be possible to examine defects in levator ani subdivisions in women with pelvic floor dysfunction. Whether or not subdivisions of the levator can reliably be identified in women with disease remains to be determined.

## REFERENCES

1. Boyles SH, Weber AM, Meyn L. Procedures for pelvic organ prolapse in the United States, 1979–1997. *Am J Obstet Gynecol* 2003;188:108–15. [PubMed: 12548203]
2. Halban, J.; Tandler, J. *Anatomie und aetiologie der genitalprolapse beim weibe*. Braumueller; Wien, Austria: 1907.
3. Smith WC. The levator ani muscle; its structure in man, and its comparative relationships. *Anat Rec* 1923;26:175–203.
4. Berglas B, Rubin IC. Study of the supportive structures of the uterus by levator myography. *Surg Gynecol Obstet* 1953;97:677–92. [PubMed: 13113550]
5. Strohbehn K, Ellis JH, Strohbehn JA, DeLancey JO. Magnetic resonance imaging of the levator ani with anatomic correlation. *Obstet Gynecol* 1996;87:277–85. [PubMed: 8559539]

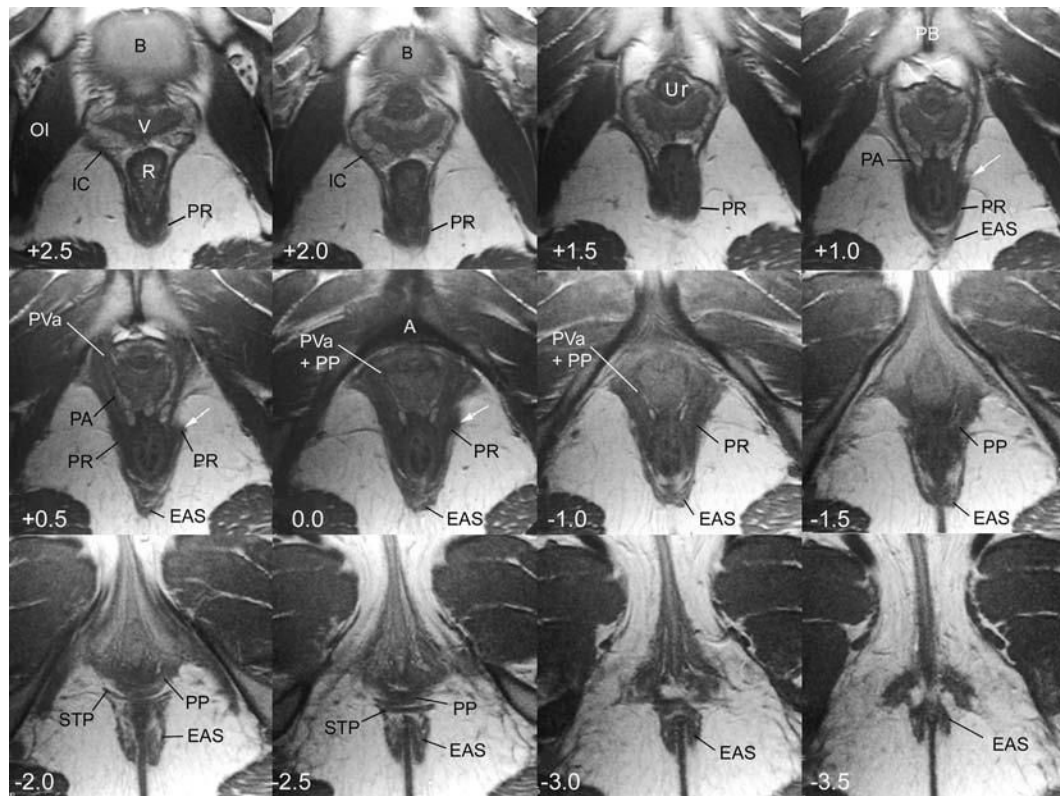
6. Tunn R, Delancey JO, Howard D, Ashton-Miller JA, Quint LE. Anatomic variations in the levator ani muscle, endopelvic fascia, and urethra in nulliparas evaluated by magnetic resonance imaging. *Am J Obstet Gynecol* 2003;188:116–21. [PubMed: 12548204]
7. Kirschner-Hermanns R, Wein B, Niehaus S, Schaefer W, Jakse G. The contribution of magnetic resonance imaging of the pelvic floor to the understanding of urinary incontinence. *Br J Urol* 1993;72:715–8. [PubMed: 8281401]
8. Hoyte L, Fielding JR, Versi E, Mamisch C, Kolvenbach C, Kikinis R. Variations in levator ani volume and geometry in women: the application of MR based 3D reconstruction in evaluating pelvic floor dysfunction. *Arch Esp Urol* 2001;54:532–9. [PubMed: 11512397]
9. Federative Committee on Anatomical Terminology. Terminologia anatomica: international anatomical terminology. Thieme; Stuttgart, Germany: 1998.
10. Kearney R, Sawhney R, DeLancey JO. Levator ani muscle anatomy evaluated by origin-insertion pairs. *Obstet Gynecol* 2004;104:168–73. [PubMed: 15229017]
11. Chou Q, DeLancey JO. A structured system to evaluate urethral support anatomy in magnetic resonance images. *Am J Obstet Gynecol* 2001;185:44–50. [PubMed: 11483902]
12. Nichols DH, Milley PS, Randall CL. Significance of restoration of normal vaginal depth and axis. *Obstet Gynecol* 1970;36:251–6. [PubMed: 5428492]



**Fig. 1.**

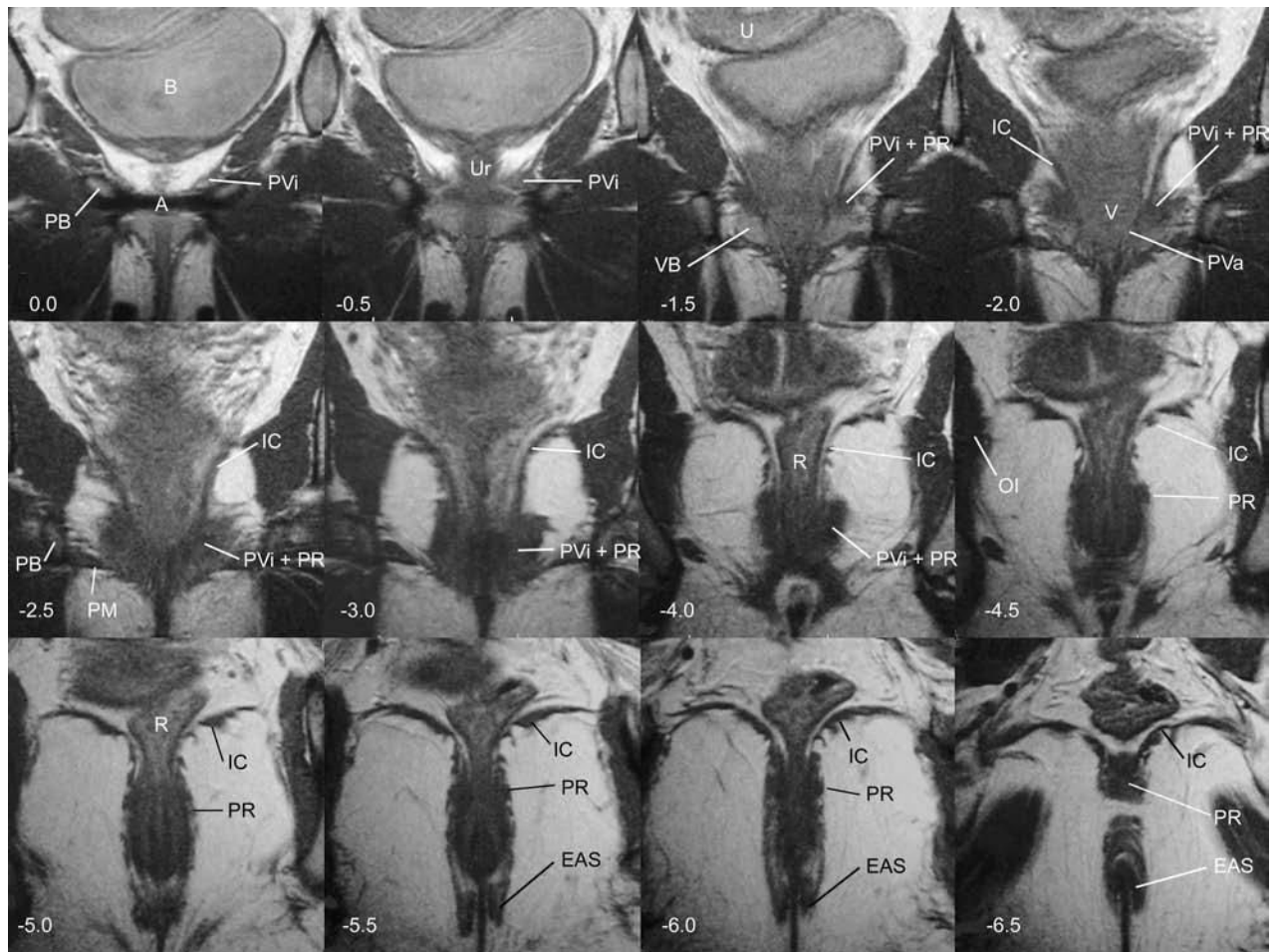
**A.** Three-dimensional model of levator ani subdivisions including the pubic bone and pelvic viscera. This model was created by using the magnetic resonance images shown in Figures 2, 3, and 4. The pubovaginal, puboperineal, and puboanal muscles are all combined into a single structure, the pubovisceral muscle. Inferior, left 3-quarter view. **B.** The same model without the pubic bone. PB, pubic bone; V, vagina; U, uterus; Ur, urethra; B, bladder; IC, iliococcygeus muscle; PR, puborectal muscle; PVi, pubovisceral muscle; EAS, external anal sphincter. © DeLancey 2006.





**Fig. 2.**

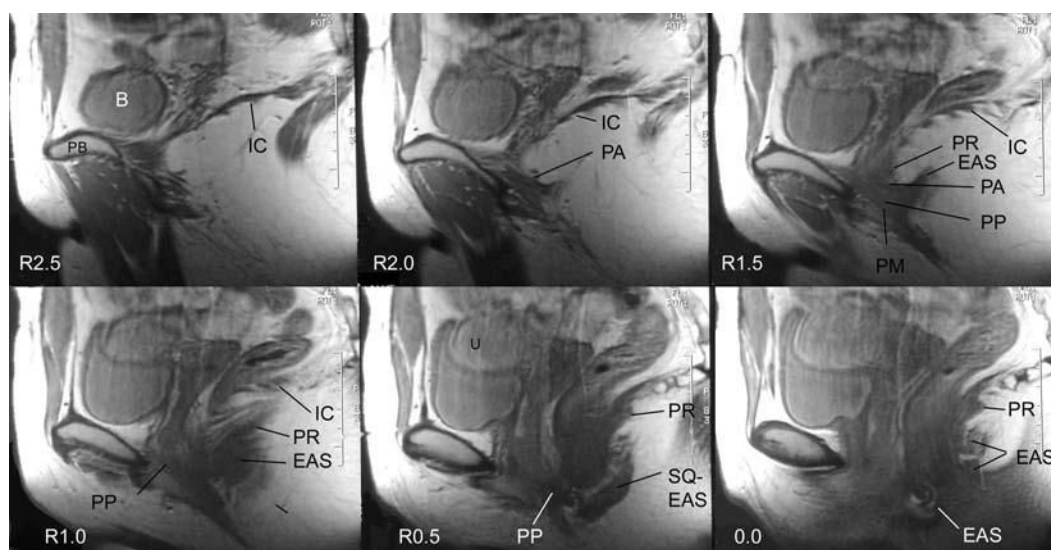
Axial scan of 25-year-old nullipara showing subdivisions of the levator. Level of scan in centimeters relative to the arcuate pubic ligament (*A*) is indicated in lower left corner with positive numbers cranial to the ligament and negative numbers caudal. Additional abbreviations: PP, puboperineal muscle; PVa, pubovaginal attachment; PA, puboanal muscle; OI, obturator internus muscle; STP, superficial transverse perineal muscle; R, rectum. *White arrows* indicate puborectalis muscle progression. © DeLancey 2006.



**Fig. 3.**

Coronal scans of the same subject depicted in Figure 2. The level of the scan in centimeters relative to the arcuate pubic ligament is indicated in the lower left corner with negative numbers dorsal to the ligament. Note that scans  $-1.0$  and  $-3.5$  have been omitted so that other scans could be included. Additional abbreviations: VB, vestibular bulb; PM, perineal membrane. © DeLancey 2006.





**Fig. 4.** Sagittal images of the same subject from the right side of the pelvis. The level of the scan in centimeters to the right of the midsagittal plane is indicated in the lower left corner. Additional abbreviations: SQ-EAS, subcutaneous external anal sphincter. © DeLancey 2006.

**Table 1**  
Characteristic Features and Percentage Visibility and Percent Agreement for Visibility

Levator Ani Subdivision	Axial MRI Scan (Fig. 2)	Coronal MRI Scan (Fig. 3)	Sagittal MRI Scan (Fig. 4)
Pubovisceral			
Puboanal (% visibility; interrater agreement)	Best to demonstrate fiber insertion into intersphincteric space (panels: +1.0, +0.5) (100%; 100%)	Cannot be distinguished (panels: -2.5, -3.0, -4.0)(0%; 100%, <i>Not a characteristic feature</i> )	Muscle in intersphincteric space, seen rarely (panels: R1.5, R2.0)(22%; 56%, <i>Not a characteristic feature</i> )
Puboperineal (% visibility; interrater agreement)	Insertion into perineal body often visible (panels: -1.5, -2.0, -2.5)(94%; 96%)	Cannot be distinguished (panels: -2.5, -3.0, -4.0)(0%; 100%, <i>Not a characteristic feature</i> )	Fiber direction often visible (panels: R0.5 through R1.5) (90%; 80%)
Pubovaginal attachment (% visibility; interrater agreement)	Good view of attachment between muscle and vaginal wall (panels: +0.5, 0.0)(96%; 92%)	Fusion with vaginal wall evident (panel: -0.0)(94%; 96%)	Attachment not seen(22%; 56%, <i>Not a characteristic feature</i> )
Puborectal (% visibility; interrater agreement)	Loop behind rectum visible, although not in a single scan (panels: +2.5 to +0.5) (100%; 100%)	Bulk of muscle easily seen in midbelly lateral to pubovisceral (panels: -1.5 through -7.0)(98%; 96%)	Fiber direction and “bump” behind anorectal junction demonstrated well (panels: R1.0 through 0.0)(98%; 96%)
Iliococcygeal (% visibility; interrater agreement)	Origin from arcus tendineus levator ani seen (panels: +2.5, +2.0) (100%; 100%)	Wings of muscle and lateral origin seen (panels: -2.0 through -7.0)(100%; 100%)	Insertion into coccyx and sacrum, “shelf”-like appearance (panels: R2.5 through 1.0) (100%; 100%)

MRI, magnetic resonance imaging.

This table is a summary of the characteristic features of the subdivisions of the levator ani for each scan plane. It provides an overview of the features that are shown in the figures and an indication of which panels demonstrate each feature.