

Brachydactyly Type B: Clinical Description, Genetic Mapping to Chromosome 9q, and Evidence for a Shared Ancestral Mutation

Yaoqin Gong,^{1,2} David Chitayat,³ Bronwyn Kerr,⁴ Taiping Chen,⁵ Riyana Babul-Hirji,³ Adatiya Pal,³ Michael Reiss,⁵ and Matthew L. Warman¹

¹Department of Genetics and Center for Human Genetics, Case Western Reserve University School of Medicine and University Hospitals of Cleveland, Cleveland; ²Department of Genetics, Shandong Medical University, Jinan, Peoples' Republic of China; ³Prenatal Diagnosis Program, University of Toronto, Toronto; ⁴Regional Genetics Service, Royal Manchester Children's Hospital, Manchester; and ⁵Department of Internal Medicine and Yale Cancer Center, Yale University School of Medicine, New Haven

Summary

Autosomal dominant brachydactyly type B (BDB) is characterized by nail aplasia with rudimentary or absent distal and middle phalanges. We describe two unrelated families with BDB. One family is English; the other family is Canadian but of English ancestry. We assigned the BDB locus in the Canadian family to an 18-cM interval on 9q, using linkage analysis (LOD score 3.5 at recombination fraction [θ] 0, for marker D9S938). Markers across this interval also cosegregated with the BDB phenotype in the English family (LOD score 2.1 at $\theta = 0$, for marker D9S277). Within this defined interval is a smaller (7.5-cM) region that contains 10 contiguous markers whose disease-associated haplotype is shared by the two families. This latter result suggests a common founder among families of English descent that are affected with BDB.

Introduction

Congenital hand anomalies occur frequently in human populations (Ivy 1957; Scott-Emuakpor and Madueke 1976). Chromosomal disorders, single-gene disorders, and teratogenic exposures are among the recognized causes of congenital hand defects, with diverse phenotypes in affected individuals reflecting this etiologic heterogeneity. Brachydactyly, the "shortening of the digits due to anomalous development of any of the contributing phalanges or metacarpals of which they consist" (Bell 1951, p. 1), constitute one group of hand malformations. Heritable brachydactyly can occur either as an

isolated trait or as a component feature of a pleiotropic syndrome.

The heritable brachydactylies have been classified into subtypes based on their distinct patterns of skeletal-element involvement (e.g., see Bell 1951; Fitch 1979). Although locus heterogeneity is a likely cause for the different clinical subtypes, locus heterogeneity has also been demonstrated within subtypes. For example, three different loci have been implicated in causing syndromic forms of brachydactyly type E (BDE): GNAS1 on 20q in patients with Albright hereditary osteodystrophy (AHO) (Weinstein et al. 1990), chromosomal deletions of 2q37 in an AHO-like disorder (Wilson et al. 1995), and a novel locus on 12p in families with BDE associated with short stature and hypertension (Schuster et al. 1996). Similarly, mutations within CDMP1 on chromosome 20 have been found in several individuals with brachydactyly type C (BDC) (Polinkovsky et al. 1997), whereas linkage analysis suggests that a second BDC locus resides on human chromosome 12q (Polymeropoulos et al. 1996).

Type B brachydactyly (BDB [MIM 113000]) is readily distinguished from other types of brachydactyly by the involvement of distal phalanges and the occurrence of nail aplasia (Bell 1951). It was the first of the heritable brachydactylies described in the medical literature (Kellie 1808). In this paper we describe two unrelated kindreds affected with isolated BDB and report the linkage mapping of a BDB locus to human chromosome 9q. We also suggest that the two families have a common ancestral mutation, on the basis of their sharing of a 10-marker haplotype within the defined interval. We evaluated one candidate gene, that for the transforming growth-factor beta type I receptor (TGFB1, also known as "ALK5"), and did not identify a mutation in either family.

Subjects and Methods

Clinical Description

Family 1.—This family was ascertained through individual III-5, who sought genetic counseling at the Uni-

Received August 25, 1998; accepted for publication December 7, 1998; electronically published January 21, 1999.

Address for correspondence and reprints: Dr. Matthew L. Warman, Department of Genetics, BRB-719, CWRU School of Medicine, 2109 Adelbert Road, Cleveland, OH. E-mail: MLW14@po.cwru.edu

© 1999 by The American Society of Human Genetics. All rights reserved.
0002-9297/99/6402-0028\$02.00

versity of Toronto. The consultand and several of her relatives (fig. 1) kindly permitted us to interview and examine them during a family reunion. No unaffected relative has had an affected child. All affected individuals have reduction deformities of digits 2–5 (fig. 2). Nails on these digits are either absent or hypoplastic. Thumbs and great toes look normal in all affected family members; however, on x-ray, a cleft distal phalanx of both thumbs was observed in family members III-5 and III-6. All family members have normal intelligence. No medical problems are reported to cosegregate with the hand phenotype. No distinctive facial appearance is thought to segregate with the family's hand phenotype. High-resolution ultrasound had been performed prenatally to evaluate digital formation in two affected members of the family (IV-1 and IV-4); brachydactyly was observed as early as the 14th gestational week in IV-4.

Family 2.—This family was ascertained when the wife of III-3 sought genetic counseling at the Royal Manchester Children's Hospital. She was accompanied by individual II-1. II-1 provided a history of hand anomalies in several generations of her family, although the location of her affected aunts and uncles was unknown; she believed that those people with abnormal hands could be identified from family photographs, because of a facial similarity. In the extended family, no unaffected persons had affected children, and the phenotype in all affected individuals was similar, apart from one person with additional hand syndactyly. Examination of II-1 (fig. 3) showed that she had normal thumbs with short digits, most marked in the 4th and 5th digits, with only proximal phalanges and tiny middle phalanges present. A single short middle/distal phalanx was present on the 2d and 3d fingers, with a tiny nail on the 2d digit bilaterally. In the feet, although no abnormality had been

noted apart from both a short 4th toe with a missing nail and a thickened nail on the 3d toe, on x-ray the distal phalanges were found to be missing on toes 2–5 (not shown). DNA was collected from all family members indicated in figure 1, and III-1 and IV-1 were visited at home. III-1's hand and foot findings were very similar to those for her mother, although her middle phalanges were shorter on the 2d finger and were absent on the 5th finger. Her son, IV-1, had been born with a red bleb on the right 4th finger tip, which eventually went black and fell off. Facially, IV-1 had a strong resemblance to his affected mother and grandmother, with a high nasal bridge, long narrow nose, and flared ala nasae (fig. 3); this appearance was different from that of his unaffected sister.

DNA Collection and Genotyping

Informed consent was obtained from all participants, and blood or cheek swabs were collected for DNA extraction. Blood DNA was extracted by standard methods. Cheek-swab DNA was obtained by incubation of the swab in 600 μ l of 50 mM NaOH for 10 min at 95°C and subsequent addition of 50 μ l of 1 M Tris pH 8.0. All polymorphic markers used for linkage analysis were simple-sequence-repeat polymorphisms (SSRP) purchased from Research Genetics. The version 6A screening set was used in the initial screen. Additional SSRP markers flanking linked markers were purchased as needed. SSRP reactions were performed with either 50 ng of blood DNA or 3 μ l of the cheek-swab extract, per PCR reaction. Markers were amplified in 10- μ l reactions containing 1 \times PCR buffer, 200 μ M of each dNTP, 0.2 μ M each primer, and 0.05 units of *Taq* polymerase. All forward primers were end-labeled with 33 P, by means of

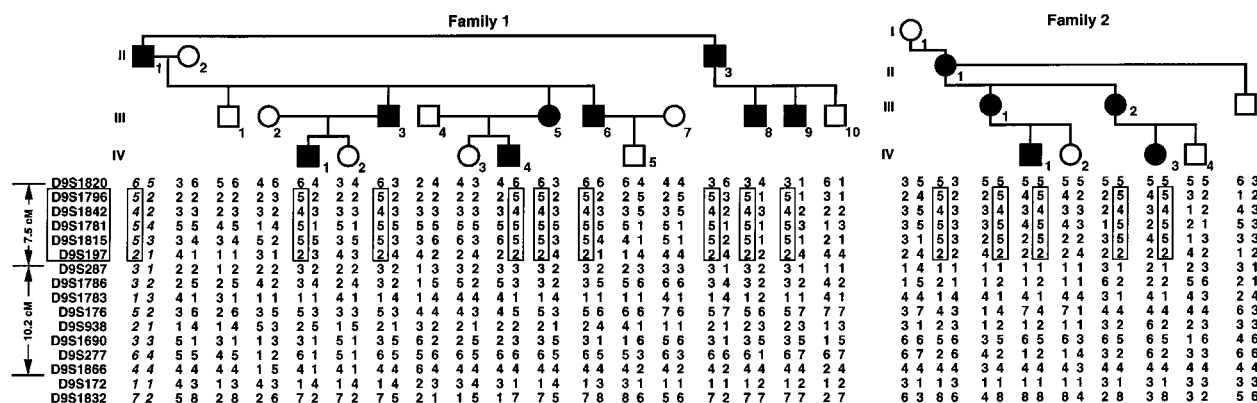


Figure 1 Pedigree and linkage data for the two BDB kindreds. DNA was unavailable from individual II-1 of family 1; therefore, his inferred genotype is shown in italics. When deducible, paternally derived alleles are at the left—and maternally derived alleles are at the right—of each individual genotype. Boxed markers are part of the 10-contiguous-marker disease-associated haplotype that is common to both families. Other markers (not shown) that are part of this shared haplotype include D9S1836, D9S1841, D9S1803, D9S196, and D9S1689; also not shown are markers D9S1816, D9S280, and D9S1851, which are telomeric of the shared haplotype.

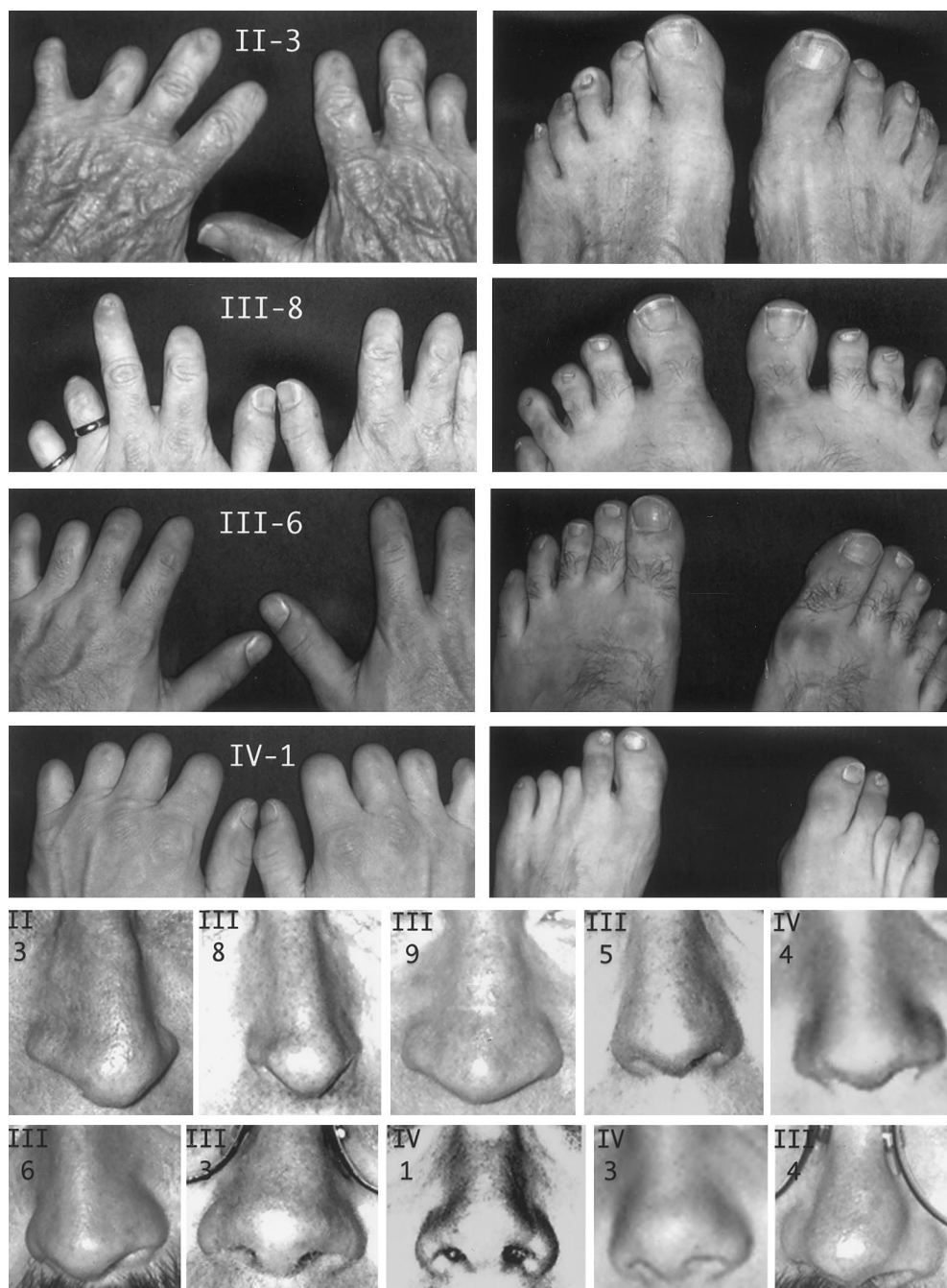


Figure 2 Finger, toe, and nasal features in members of family 1. Hands and feet are shown side-by-side, for the each individual. Identifiers are the same as in fig. 1. Apical involvement can be asymmetrical within an individual (e.g., note the middle-finger length in III-8) and can differ between individuals. Fingernails need not be completely absent (e.g., a left 3d fingernail is present in III-8). Toenails are less commonly affected than fingernails. Thumbs and great toes appear normal. No specific nasal configuration appears to cosegregate with the BDB phenotype. Note that the noses of unaffected individuals III-4 and IV-3 are included in the figure.

T4 polynucleotide kinase. PCR conditions included an initial denaturation for 4 min at 95°C, followed by 35 cycles of 40 s at 95°C, 40 s at 56°C, and 60 s at 72°C and by a final extension for 10 min at 72°C. PCR products were separated by denaturing-gel electrophoresis, and alleles were detected by autoradiography.

Linkage Calculations

Two-point LOD scores between the disease gene and each marker were calculated by the MLINK subroutine of the LINKAGE software package (Lathrop et al. 1984). Linkage calculations assumed autosomal domi-

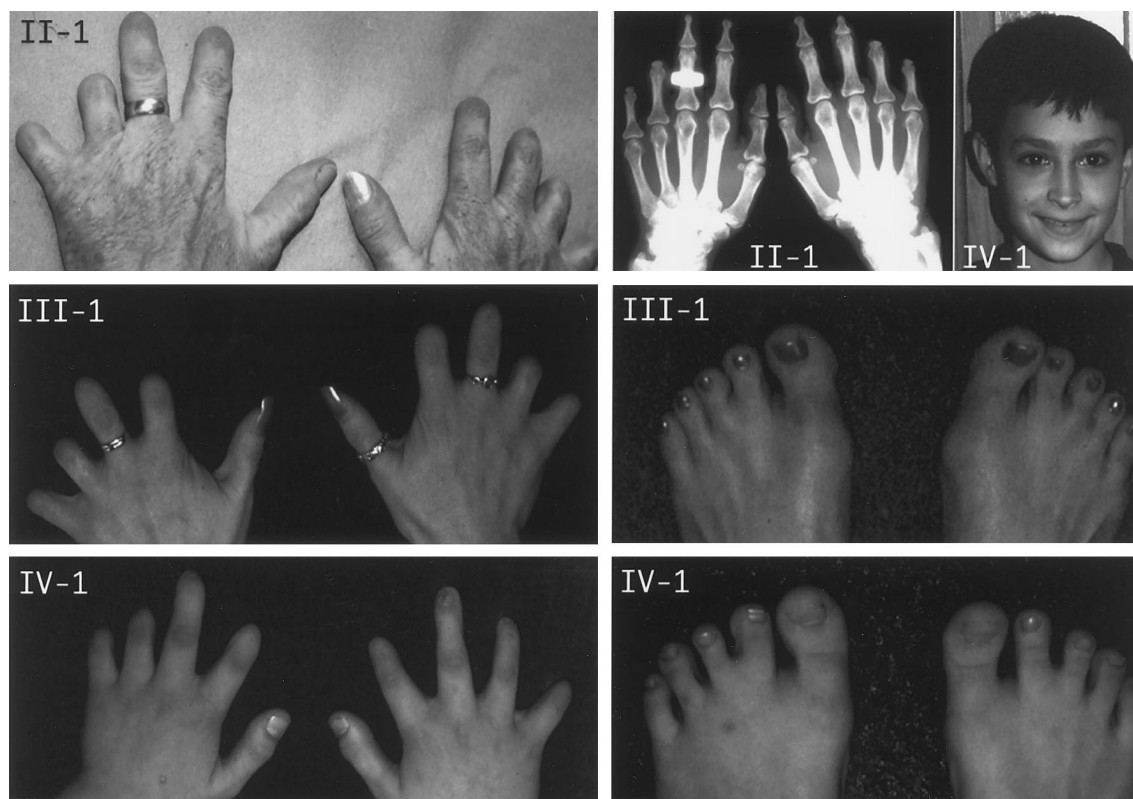


Figure 3 Finger, toe, hand x-ray, and facial features in members of family 2. Identifiers are the same as in fig. 1. Note normal-appearing metacarpals and proximal phalanges—but rudimentary middle/distal phalanges—in the hand radiograph of individual II-1. Digits 2 and 3 on the left hand appear to have a distal phalanx articulating with a proximal phalanx. However, this may be a misshapen middle phalanx, rather than a true distal phalanx. Note that affected individual IV-1 has normal facial features.

nant inheritance with complete penetrance and phenocopy and mutant-allele frequencies of 10^{-4} in the general population. Allele frequencies at each locus were set equal to $1/N$, where N is the number of different alleles that we observed in the two kindreds.

Evaluation of the TGFBR1 Locus

Nine primer pairs (Chen et al. 1998) derived from TGFBR1 genomic sequence (Vellucci and Reiss 1997) were used to PCR amplify the nine exons that contain coding sequence in patient and control DNA. For exons 2–9, PCR conditions were identical to those used for genotyping as described above, except that the primers were not radioactively end-labeled and the PCR-reaction volume size was 50 μ l. To PCR amplify exon 1, which is GC rich, a GC-Advantage kit from Clontech was used. PCR products were purified and cycle sequenced with 33 P-end-labeled primers, by the dsDNA Cycle Sequencing System (Gibco/BRL), according to the manufacturer's instructions.

Results

BDB was inherited as an autosomal dominant trait in both families. Clinical features common to both kindreds included reduction deformity of the digits, with aplasia of most fingernails; toenails were less commonly affected. Thumbs and great toes appeared normal to visual inspection. Hands were more severely affected than feet. Radiographically, metacarpal and proximal phalanges appeared normal, whereas middle and distal phalanges were shortened or missing. In some instances, a single distal phalanx appeared to articulate with the proximal phalanx. However, we could not determine whether this skeletal element was a true distal phalanx or a malformed middle phalanx.

Neither family had evidence of nonpenetrance. Individuals could have asymmetric hand or foot involvement (figs. 2 and 3). The extent of apical involvement also differed between related individuals (figs. 2 and 3). Two individuals from family 1 had radiographically detectable cleft distal phalanges of the thumbs but not of the great toes; the clefts had not been suspected on the basis of visual inspection.

DNA from family 1 was used in the initial genome-wide screen for the BDB locus, since this family is large enough to yield a LOD score >3.0 , with a fully informative marker. Four DNA samples (fig. 1, individuals II-3, III-3, III-5, and III-6) were tested, with each version 6A autosomal SSRP marker, for both heterozygosity status and the sharing of a common allele. Thirty-five SSRP markers within the screening set contained an allele shared by all four individuals. These 35 SSRPs were then tested in the entire family. Significant linkage was observed between the BDB locus and one of these markers, D9S938 (LOD score 3.5 at $\theta = 0$). Linkage between the disease locus and other chromosome 9q markers (Dib et al. 1996) was then evaluated in both families (fig. 1). Positive LOD scores at $\theta = 0$ were obtained for markers spanning an 18-cM interval. In family 2, the fully informative marker D9S277 yielded a maximum LOD score of 2.1 at $\theta = 0$. When data from both families were combined, a maximum two-point LOD score of 5.2 ($\theta = 0$) was obtained, with marker D9S1815.

Comparison of disease-associated haplotypes in the two families revealed an identical 10-SSRP-marker haplotype, spanning 7.5 cM, within the larger interval (fig. 1). Since both families have ancestors from the United Kingdom, this result suggests that they share a common founder. It should be noted that D9S1815, which yielded the highest combined two-point LOD score, is part of the 10-marker haplotype.

The TGFBR1 gene has been mapped to chromosome 9q22 (Pasche et al. 1998). Radiation hybrid mapping clearly places TGFBR1 within the 18-cM interval defined within family 1—and, possibly, within the 7.5-cM interval common to both families (Schuler et al. 1996). Because functional haploinsufficiency for the TGF β family member CDMP1 had previously been identified as one cause of BDC (Polinkovsky et al. 1997), and since murine null mutations for the TGF β antagonist “noggin” have also been associated with alterations in skeletal-element formation (Brunet et al. 1998), TGFBR1 seemed a reasonable candidate gene to evaluate in BDB. All nine exons of TGFBR1 were PCR amplified and sequenced in one affected member of each kindred. No disease-causing mutations were detected in either the coding sequence or the adjoining intronic splice sites. Heterozygosity for a common intronic polymorphism in intron 7 of the gene was observed in individual III-5 of family 1. Individual III-1 of family 2 was found to be heterozygous for a previously reported polyalanine-tract polymorphism in exon 1 (Pasche et al. 1998). These results exclude deletion of the entire TGFBR1 locus as the cause of BDB.

Discussion

Both families described herein had features of BDB that were similar to those elsewhere reported in other

families of English ancestry (MacKinder 1857; Clarke 1915; Cragg and Drinkwater 1917; MacArthur and McCullough 1932; Wells and Platt 1934; Malloch 1957; Battle et al. 1973). Common to all families are fingernail aplasia or hypoplasia involving digits 2–5; reduction deformity of the hands and the feet, with radiographically demonstrated hypoplasia or absence of distal and middle phalanges; normal-appearing great toes; and absence of major extra-apical manifestations. In family 1, two affected individuals had a cleft distal phalanx of the thumb. This was not observed in the one member of family 2 for whom x-rays were obtained. Several individuals in previously published kindreds with BDB also had clefts or even duplications of the distal phalanx of the thumb; however, the occurrence of thumb involvement was variable within individual kindreds. The occurrence of a distinct facies in BDB has been proposed (Houlston and Temple 1994). Individuals II-3 and III-8 of family 1 do share a nasal appearance similar to that described by Houlston and Temple (1994); however, other facial features thought to be associated with BDB, such as down-slanting palpebral fissures and short philtrums, were not present in either of the two families in our study. We also could not recognize a consistent nasal configuration segregating with the BDB phenotype in family 1 (fig. 2).

Significant linkage is observed between BDB and SSRP markers contained within an 18-cM interval on chromosome 9q. Most intriguing is that both families share a common haplotype for 10 contiguous SSRP markers within this defined interval (fig. 1). Four BDB kindreds—three English and one Canadian—had ancestors from Lincolnshire, Nottingham, or Manchester, in the northwest region of England (Clarke 1915; Cragg and Drinkwater 1917; Wells and Platt 1934; Malloch 1957; Battle et al. 1973), leading to speculation that the families may share a common ancestor (MacArthur and McCullough 1932; Battle et al. 1973). Supporting this is our confirmation (authors' unpublished data) that this disease-associated haplotype (from D9S1836 to D9S197) is shared by two additional BDB families, which were investigated independently by Oldridge et al. (1999).

The BDB candidate interval is centromeric of the LMX1B gene, which causes another nail-dysplasia disorder, nail-patella syndrome (Dreyer et al. 1998). If the 10-marker haplotype is assumed to have originated from a shared founder, then the candidate interval can be reduced to 7.5 cM between the SSRP markers D9S1820 and D9S1816; this roughly coincides with bands 9q21-22 on the cytogenetic map. Evaluation of the human gene map, radiation hybrid map, and orthologous murine map (Mouse Genome Informatics; GeneMap'98) suggested one candidate gene, TGFBR1, because of the involvement of TGF β family members

and their antagonists in skeletal patterning. We amplified genomic DNA encoding TGFBR1 and did not detect any exonic or splice-site mutations. Since the gene was evaluated by PCR, we may not have detected small deletions removing individual exons of the gene; however, we did find heterozygosity for common polymorphisms in an affected member of each kindred, which precludes deletion of the entire gene as a cause of BDB.

The precise mechanisms for the digital reductions in BDB are not known. Digital involvement in the autosomal recessive disorders murine myelencephalic blebs (*my*) (Bagg 1925) and lapine hereditary brachydactyly (Greene and Saxton 1939) is suggested to resemble that occurring in human BDB (Bean 1925; MacArthur and McCullough 1932; Greene and Saxton 1939; Fitch 1979). Murine myelencephalic blebs maps to mouse chromosome 3, which is not known to be orthologous with human chromosome 9. Whether lapine brachydactyly maps to a region orthologous with human BDB is unknown. Each of these animal phenotypes was thought to have a vascular or lymphatic disruption as the underlying cause of the brachydactylous phenotype (Bagg 1925; Greene and Saxton 1939; Inman 1941). An embryologic disruption of apical skeletal development may also explain the BDB phenotype, with differences in the timing of cartilage anlage condensation and differentiation (chondrification) within the developing apical skeleton accounting for the distinct pattern of digital involvement. Chondrification of fingers commences during the 7th gestational week, and the distal phalanx of the thumb is formed several days before the distal phalanges of digits 2–5 (Larsen 1993, pp 282–290; O’Rahilly and Müller 1996, pp 349–360). Toe development lags several days behind finger development but follows the same general pattern of chondrification. Fingernails begin to develop by the 9th gestational week, several weeks ahead of toenails. Consequently, one could speculate that, were disruption of limb development the likely cause of BDB, then the timing of the disruption would likely occur around the 7th or 8th gestational week. Further support for a disruptive mechanism in the causation of BDB is the appearance of scarring at the fingertips in several patients (Battle et al. 1973) and the lack of normal dermatoglyphic patterns (MacArthur and McCullough 1932; Battle et al. 1973). The red bleb occurring on one of the fingers of individual IV-1 of family 2, which subsequently went black and fell off, has been described in both the murine and the rabbit disorders. Interestingly, in lapine brachydactyly, one of the radiographic consequences of disrupted digital development is the change in radiographic appearance of middle phalanges into distal phalanges, similar to the radiological changes observed in patients with BDB. We are not aware of individuals with BDB having tissue strands emanating from their affected digits, similar to those re-

ported in the autosomal dominant disorder Adams-Oliver syndrome or in neonates with disruptions associated with amniotic bands. This may argue against a disruptive mechanism for BDB or may reflect differences in the timing of apical disruption in these conditions.

The striking similarity, in hand involvement, among many families with both BDB and English ancestry may result from a single ancestral mutation at the BDB locus. However, typical features of BDB have been described in families who either lack English ancestry (Cuevas-Sosa and García-Segur 1971) or have de novo mutations that apparently arose in a recent ancestor (Bass 1968). We cannot determine whether this reflects locus or allelic heterogeneity for BDB or a recurrent mutation causing the phenotype, similar to that which has been reported in achondroplasia (Shiang et al. 1994). This distinction may prove important when one is considering clinical differences between patients for whom BDB is inherited as an isolated trait and those for whom it is a component of a pleiotropic syndrome. BDB has been reported as a component feature in several Mendelian genetic disorders (e.g., see Cooks et al. 1985; Pitt and Williams 1985; Kumar and Levick 1986; Thompson and Baraitser 1988; Tonoki et al. 1990). However, the pattern of hand and foot involvement in these disorders differs from that which we and others have observed in isolated BDB. For example, in Cooks syndrome there may be nail hypoplasia or aplasia of all digits, including thumbs and great toes (Cooks et al. 1985). In Sorsby syndrome, duplications of the distal phalanges of the thumbs and of both the proximal and distal phalanges of the great toes have been described, as has aplasia of the nails on the great toes (Thompson and Baraitser 1988). Although the hand involvement in syndromic BDB is different from that in isolated BDB, one or more of these syndromes could still be allelic variants of the isolated BDB locus that we have assigned to human chromosome 9q.

Acknowledgments

This work was supported by National Institutes of Health grant AR43827 and by a Biomedical Sciences Grant from the March of Dimes Birth Defects Foundation. The authors thank the families for participating in this study and thank J. Hurvitz and S. Bolk for sharing their scientific expertise.

Electronic-Database Information

Accession numbers and URLs for data in this article are as follows:

GeneMap’98, <http://www.ncbi.nlm.nih.gov/genemap98/>
Mouse Genome Informatics, <http://www.informatics.jax.org/>
Online Mendelian Inheritance in Man (OMIM), <http://www.ncbi.nlm.nih.gov/Omim> (for BDB [MIM 113000])

References

- Bagg HJ (1925) Hereditary abnormalities of the limbs, their origin and transmission. *Am J Anat* 43:167-220
- Bass HN (1968) Familial absence of middle phalanges with nail dysplasia: a new syndrome. *Pediatrics* 42:318-323
- Battle HI, Walker NF, Thompson MW (1973) MacKinder's hereditary brachydactyly: phenotypic, radiological, dermatoglyphic and genetic observations in an Ontario family. *Ann Hum Genet* 36:415-424
- Bean AM (1925) A morphological analysis of the foot abnormalities occurring in the descendants of X-rayed mice. *Am J Anat* 43:221-246
- Bell J (1951) Brachydactyly and symphalangism. In: Penrose LS (ed) *The treasury of human inheritance*. Vol 5: Hereditary digital anomalies. University of Cambridge Press, Cambridge, pp 1-31
- Brunet LJ, McMahon JA, McMahon AP, Harland RM (1998) Noggin, cartilage morphogenesis, and joint formation in the mammalian skeleton. *Science* 280:1455-1457
- Chen T, Carter D, Garrigue-Antar L, Reiss M (1998) Transforming growth factor β type I receptor kinase mutant associated with metastatic breast cancer. *Cancer Res* 58:4805-4810
- Clarke DS (1915) Congenital hereditary absence of some of the digital phalanges. *Br Med J* 2:255
- Cooks RG, Hertz M, Katznelson MBM, Goodman RM (1985) A new nail dysplasia syndrome with onychonychia and absence and/or hypoplasia of distal phalanges. *Clin Genet* 27:85-91
- Cragg E, Drinkwater H (1917) Hereditary absence of phalanges through five generations. *J Genet* 6:81-89
- Cuevas-Sosa A, García-Segur F (1971) Brachydactyly with absence of middle phalanges and hypoplastic nails. *J Bone Joint Surg* 53:101-105
- Dib C, Faure S, Fizames C, Samson D, Drouot N, Vignal A, Millasseau P, et al (1996) A comprehensive genetic map of the human genome based on 5,264 microsatellites. *Nature* 380:152-154
- Dreyer SD, Zhou G, Baldini A, Winterpacht A, Zabel B, Cole W, Johnson RL, et al (1998) Mutations in LMX1B cause abnormal skeletal patterning and renal dysplasia in nail patella syndrome. *Nat Genet* 19:47-50
- Fitch N (1979) Classification and identification of inherited brachydactylies. *J Med Genet* 16:36-44
- Greene H, Saxton J (1939) Hereditary brachydactylia and allied abnormalities in the rabbit. *J Exp Med* 69:301-314
- Houlston RS, Temple IK (1994) Characteristic facies in type B brachydactyly? *Clin Dysmorphol* 3:224-227
- Inman O (1941) Embryology of hereditary brachydactyly in the rabbit. *Anat Rec* 79:483-505
- Ivy RH (1957) Congenital anomalies. *Plast Reconstr Surg* 20:400-411
- Kellie DR (1808) Extract from a letter from Mr L. to Dr Kellie, Leith. *Edinb Med Surg J* 4:252
- Kumar D, Levick RK (1986) Autosomal dominant onychodystrophy and anonychia with type B brachydactyly and ectrodactyly. *Clin Genet* 30:219-225
- Larsen WJ (1993) *Human embryology*. Churchill Livingstone, New York
- Lathrop GM, Lalouel JM, Julier C, Ott J (1984) Strategies for multilocus linkage analysis in humans. *Proc Natl Acad Sci USA* 81:3433-3446
- MacArthur JW, McCullough E (1932) Apical dystrophy an inherited defect of hands and feet. *Hum Biol* 4:179-207
- MacKinder D (1857) Deficiency of fingers transmitted through six generations. *Br Med J* 1857:845-846
- Malloch JD (1957) Brachydactyly and symbrachydactyly. *Ann Hum Genet* 22:36-37
- Oldridge M, Temple IK, Santos HG, Gibbons RJ, Mustafa Z, Chapman KE, Loughlin J, et al (1999) Brachydactyly type B: linkage to chromosome 9q22 and evidence for genetic heterogeneity. *Am J Hum Genet* 64:578-585 (in this issue)
- O'Rahilly R, Müller F (1996) *Human embryology and teratology*. Wiley-Liss, New York
- Pasche B, Luo Y, Rao PH, Nimer SD, Dmitrovsky E, Caron P, Luzzatto L, et al (1998) Type I transforming growth factor β maps to 9q22 and exhibits a polymorphism and rare variant within a polyalanine tract. *Cancer Res* 58:2727-2732
- Pitt P, Williams I (1985) A new brachydactyly syndrome with similarities to Julia Bell types B and E. *J Med Genet* 22:202-204
- Polinkovsky A, Robin NH, Thomas JT, Irons M, Lynn A, Goodman FR, Reardon W, et al (1997) Mutations in CDMP1 cause autosomal dominant brachydactyly type C. *Nat Genet* 17:18-19
- Polymeropoulos MH, Ide SE, Magyari T, Francomano CA (1996) Brachydactyly type C gene maps to human chromosome 12q24. *Genomics* 38:45-50
- Schuler GD, Boguski MS, Stewart EA, Stein LD, Gyapay G, Rice K, White RE, et al (1996) A gene map of the human genome. *Science* 274:540-546
- Schuster H, Wienker TE, Bähring S, Bilginturan N, Toka HR, Neitzel H, Jeschke E, et al (1996) Severe autosomal dominant hypertension and brachydactyly in a unique Turkish kindred maps to human chromosome 12. *Nat Genet* 13:98-100
- Scott-Emuakpor AB, Madueke EDN (1976) The study of genetic variation in Nigeria. II. The genetics of polydactyly. *Hum Hered* 26:198-202
- Shiang R, Thompson LM, Zhu Y-Z, Church DM, Fielder TJ, Bocian M, Winokur ST, et al (1994) Mutations in the transmembrane domain of FGFR3 cause the most common genetic form of dwarfism, achondroplasia. *Cell* 78:335-342
- Thompson EM, Baraitser M (1988) Sorsby syndrome: a report on further generations of the original family. *J Med Genet* 25:313-321
- Tonoki H, Kishino T, Niikawa N (1990) A new syndrome of dwarfism, brachydactyly, nail dysplasia, and mental retardation in sibs. *Am J Med Genet* 36:89-93
- Vellucci VF, Reiss M (1997) Cloning and genomic organization of the human transforming growth factor- β type I receptor gene. *Genomics* 46:278-283
- Weinstein LS, Gejman PV, Friedman E, Kadowaki T, Collins RM, Gershon ES, Spiegel AM (1990) Mutations of the Gs alpha-subunit gene in Albright hereditary osteodystrophy

- detected by denaturing gradient gel electrophoresis. *Proc Natl Acad Sci USA* 87:8287–8290
- Wells NH, Platt M (1934) Hereditary phalangeal agenesis showing dominant Mendelian characteristics. *Arch Dis Child* 22:251–252
- Wilson LC, Leverton K, Oude Luttikhuis MEM, Oley CA, Flint J, Wolstenholme J, Duckett DP, et al (1995) Brachydactyly and mental retardation: an Albright hereditary osteodystrophy-like syndrome localized to 2q37. *Am J Hum Genet* 56:400–407