CASE REPORT

Lateral Transmandibular Approach to the Skull Base in Children: Three Case Reports

Christian Kuettner, M.D., D.D.S.,[1] M. Samii, M.D., Ph.D.,[2] and J. E. Hausamen, M.D., D.D.S., Ph.D.[1]

ABSTRACT

The choice of surgical approach to tumors of the cranial base in children is determined by strict criteria. The criteria include optimal visibility for the surgeon, minimal possible impairment of facial skull growth, and the preservation of motor and sensory nerve integrity. From 1993 to 1996, three children (6 years old, 22 months old, 6 months old, respectively) underwent surgery to resect cranial base tumors through a modified lateral transmandibular approach. In all three patients a preauricular incision with temporal and submandibular extensions was performed. After the mandible was prepared, an osteotomy was conducted cranially to the mandibular foramen. When the capitulum was temporarily disarticulated, wide access to the cranial base was provided and the tumors were resected. Two of these children were available for follow-up, and we continue to observe their development. Given the severity of their conditions, treatment yielded good results. Growth impairment of the mandible was corrected by the distraction osteogenesis technique.

KEYWORDS: Lateral transmandibular approach, skull base tumors, children

Techniques of skull base surgery were attempted to maximize the exposure of the cranial base lesion while disminishing the amount of brain retraction. A particular focus must be placed in pediatric operations. Due to unsatisfactory surgical techniques involving high loss of blood as well as unfavorable aesthetic and functional outcomes, pediatric tumors infiltrating the pterygoid muscles, the infratemporal fossa, and the central or anterior skull base were considered to be inadequately treated by surgery for a long time.[1,2] We present a modified lateral transmandibular approach[3–5] with osteotomy

Skull Base, volume 13, number 2, 2003. Address for correspondence and reprint requests: Christian Kuettner, M.D., D.D.S., Department of Oral and Maxillofacial Surgery, Hannover University Hospital, Carl-Neuberg-Strasse 1, 30625 Hannover, Germany. E-mail: Kuettner.Christian@mh-hannover.de. [1]Department of Oral and Maxillofacial Surgery; [2]Department of Neurosurgery, Hannover University Hospital, Hannover, Germany. Copyright © 2003 by Thieme Medical Publishers, Inc., 333 Seventh Avenue, New York, NY 10001, USA. Tel: +1(212) 584-4662. 1531-5010,p;2003,13,02,085,092,ftx,en;sbs00327x.

of the ascending ramus cranial of the mandibular foramen. This approach gives a wide access to the skull base.

From 1993 until 1996, three children aged between 6 months and 6 years with tumors of the cranial base underwent interdisciplinary surgery in our departments via a modified lateral transmandibular approach. Two children continue to be followed.

SURGICAL TECHNIQUE

In all patients preauricular incisions with temporal and submandibular extension were performed (Fig. 1). After the glossopharyngeal, vagus, accessory, and hypoglossal nerves were identified, the internal carotid artery was dissected up to the cranial base. The trunk of the facial nerve was dissected from the parotid gland up to the peripheral branch. From the preauricular incision the zygomatic arch was osteotomized temporarily, connected to the masseter muscle by a pedicle, and displaced caudally. The mandibula was dissected cranially on the lateral surface of the ascending ramus and then osteotomized above the mandibular foramen. The cranial segment was disarticulated at the skull base, leaving the articular disc connected by a pedicle at the temporal muscle and displaced cranially (Figs. 2–4). Thereafter, access to the cranial base was wide and the tumors were resected. The ascending mandibular ramus and zygomatic arch were refixated by mini- or micro-osteosynthetic plates (Fig. 5).

Figure 1 Preauricular incision with temporal and mandibular extensions.

CASE REPORTS

Case 1

A 6-year-old boy presented to our institution with neurologic deficits. Computed tomography (CT) showed an infiltrating process involving the central cranial base and an intracranial extension (Fig. 6). Combined radio- and chemotherapy initially led to tumor regression. However, the tumor infiltration of the cranial base structures persisted, and we decided to operate. The modified transmandibular approach was used as described earlier, and the extracranial and intracranial portions of the sarcoma were resected. The wound healed without complications. The child sustained only slight impairment of mouth-opening related to the transmandibular approach. However, we could only follow-up the boy for the next 7 months before he died from cerebral metastasis.

Case 2

CT revealed a tumor in the pterygoid fossa area associated with infiltration of the cranial base in a 15-month-old girl (Fig. 7). Radio- and chemo-

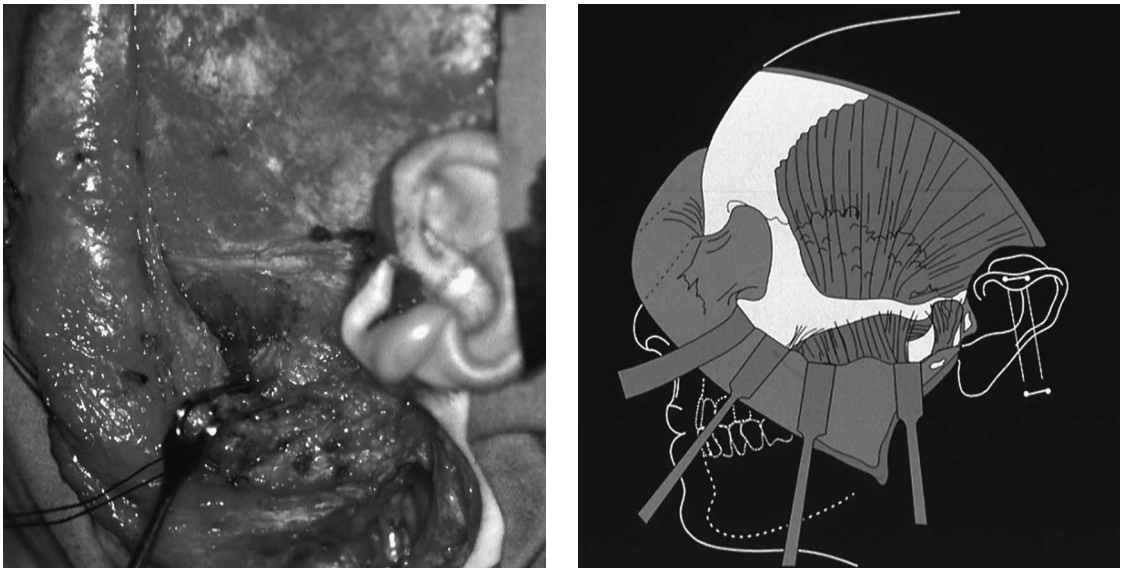

A B

Figure 2 (A) Intraoperative photograph and (B) corresponding illustration show the dissection of the zygomatic arch.

therapy reduced the tumor considerably, but weeks later the tumor recurred. At the age of 22 months the girl underwent a radical resection via a modified transmandibular approach as described. The histopathologic evaluation showed a rhabdomyosarcoma. After tumor resection, no neurological impairment could be detected (Fig. 8). During follow-up, mouth-opening was restricted to less than 5 mm. When the girl was 4 years old, transoral resection of the coronoid process became necessary. The initial retrusion of the entire mandibula was corrected favorably (Fig. 9).

Today, at the age of 10 years, the girl is still free of disease without neurological deficits. Preoperative radiation led to hypopituitarism, which is being treated by endocrinologic protocol. As a result of treatment, an inclined occlusal plane remains. Later, it could be corrected by combined distraction osteogenesis procedures and osteotomies after cranial growth ceases.

A B

Figure 3 (A) Intraoperative photograph and (B) corresponding illustration show the temporary osteotomy of the zygomatic arch, the pedicle at the masseter muscle, and caudal displacement.

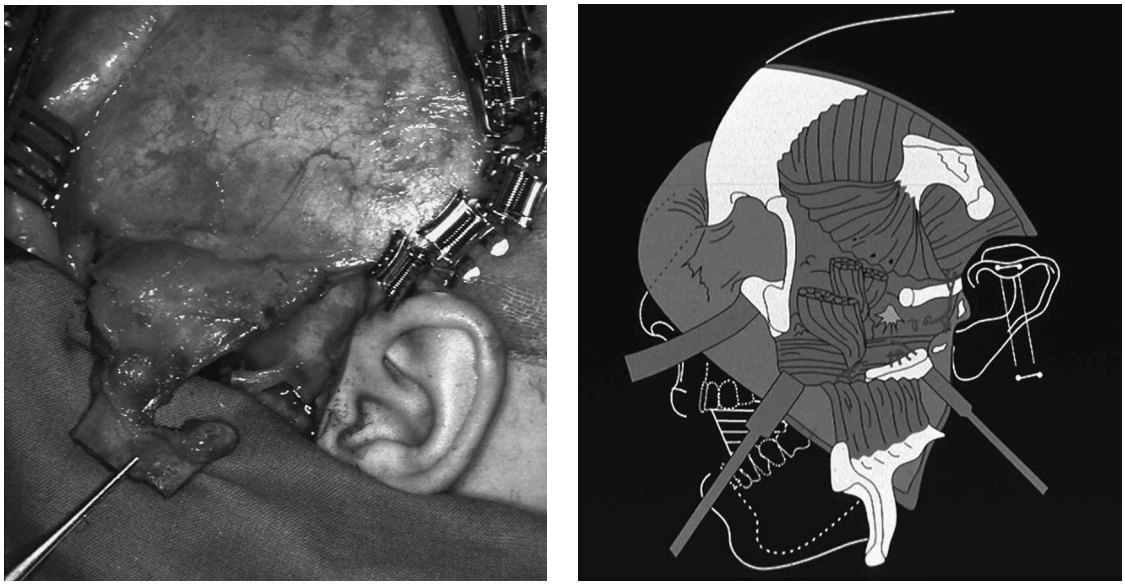

A B

Figure 4 (A) Intraoperative photograph and (B) corresponding illustration showing the mandible prepared cranially on the lateral surface of the ascending ramus. After osteotomy of the mandible above the foramen, the cranial segment was disarticulated at the skull base.

Case 3

Within the first week postpartum, an infant girl developed a progressive airway obstruction caused by a fast-growing oropharyngeal tumor. CT showed a retromaxillary neoplasm with an intracranial extension (Fig. 10). Progressive obstruction of the upper airway made local transoral resection necessary to avoid a tracheostomy. Histopathologic evaluation of the specimen verified a teratoma. At the age of 6 months, the girl underwent radical resection of the tumor through a modified transman-

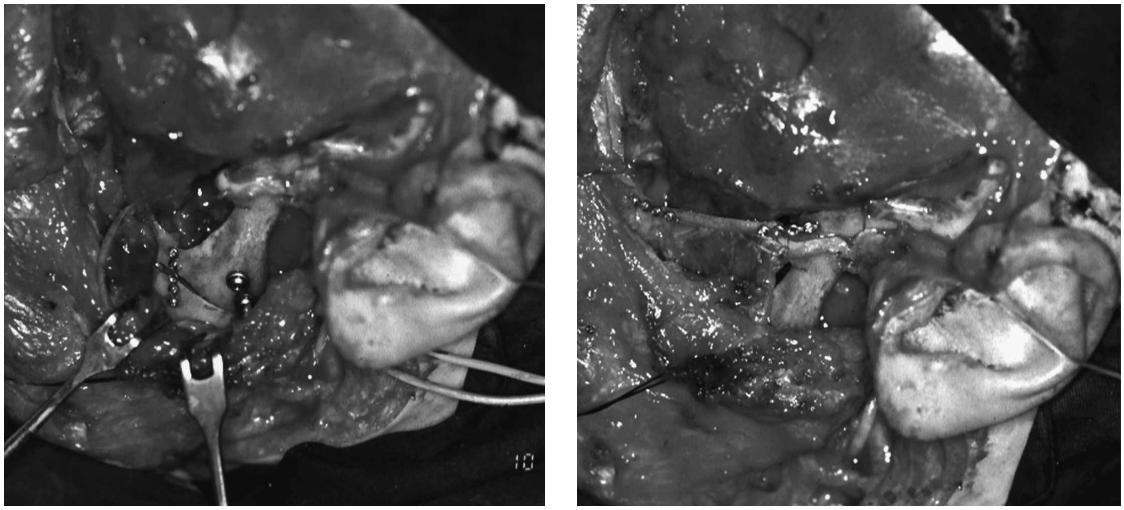

A B

Figure 5 Osteosynthesis of the (A) mandible and (B) zygomatic arch.

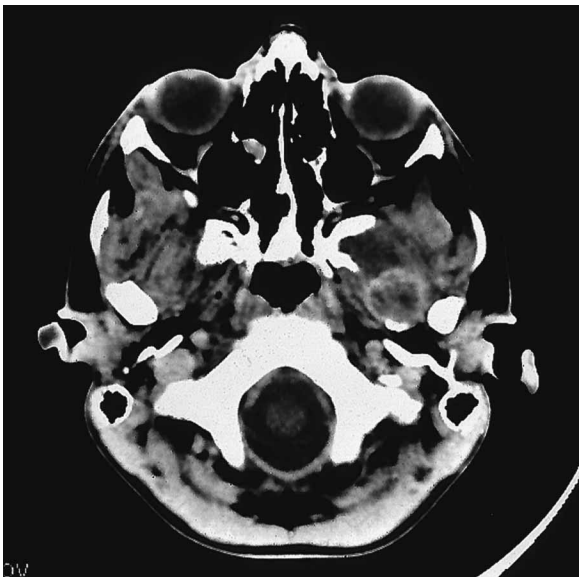

Figure 6 CT scan showing a sarcoma of the skull base in the 6-year-old boy in case 1.

dibular approach. The operative specimen confirmed the diagnosis of a benign mature teratoma. The wound healed without complications, and mouth-

Figure 7 CT showing a rhabdomyosarcoma in the pterygoid fossa and infiltrating the skull base of the 15-month-old girl in case 2.

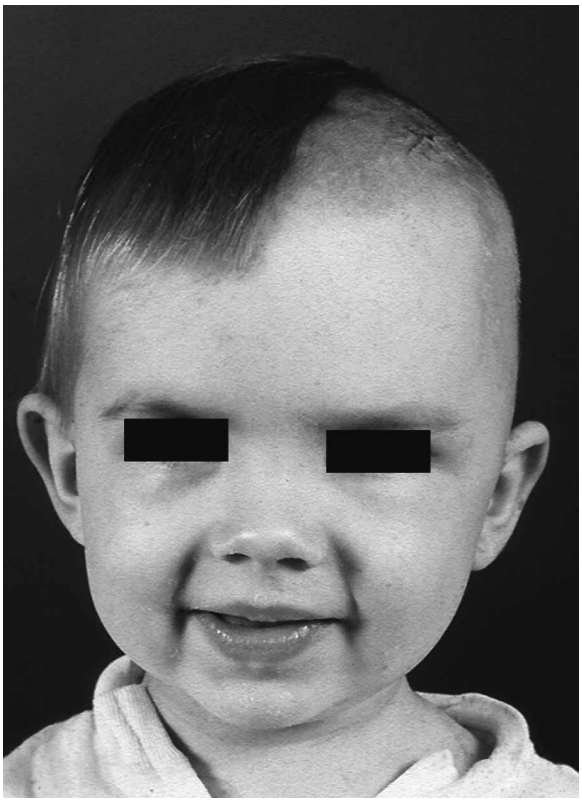

Figure 8 The 22-month-old girl in case 2 underwent a modified transmandibular approach to resect a sarcoma and showed no neurological deficit after surgery or during follow-up.

opening was not impaired. When she reached preschool age, a mandibular retrognathia was observed. It was treated successfully with osteodistraction of the ascending ramus with an external distraction device when she was 5 years old. Today, at 7 years old, the girl is free of disease and exhibits no neurologic deficits.

DISCUSSION

The goals of surgery for cranial base tumors are complete resection of the lesion and a good functional outcome.[6] These goals are more difficult to achieve in children than in adults, and many tech-

A B

Figure 9 (A) Because mouth-opening was restricted 2 years after surgery for the girl in case 2, the coronoid process had to be ablated when she was 9 years old. (B) Today, her range of opening the mouth and dentition are normal. The initial retrusion of the entire mandible was corrected favorably.

niques have been described for skull base surgery in children: transzygomatic,[7–9] supraorbital,[10] infraorbital,[1,11,12] transmandibular,[13–15] and transbasal.[16–18] A surgical approach to pediatric skull base lesions must provide good surgical access, minimize impairment of facial skull growth, prevent tooth and dental pulp injuries, and preserve the integrity of the motor and sensory nerves.

Obwegeser[4] described the temporary osteotomy of the mandible, which became a common procedure for approaching tumors involving the skull base in adults. When choosing the site of osteotomy, the surgeon must consider the location and size of the tumor and the need for a comprehensible surgical perspective. Furthermore, the expected functional and aesthetic outcomes must be considered.

The *anterior or paramedian transmandibular approaches* to the skull base require splitting the lower lip and chin area and are unacceptable in children from an aesthetic perspective. Hence, the lateral mandibular approach is preferable in children. The need for good surgical access to the skull base is apparent. The mere *disarticulation of the articular process* of the mandible does not provide a good surgical view because the mandible cannot be mobilized sufficiently. Furthermore, the vascularization of the articular process cannot be preserved with this procedure and may lead to a growth disturbance in early childhood. The mere removal of the *muscular process* only moderately improves surgical access.[2] Only a transmandibular approach provides wide access to the cranial base. The *vertical osteotomy of the ascending mandibular ramus* posterior to the inferior

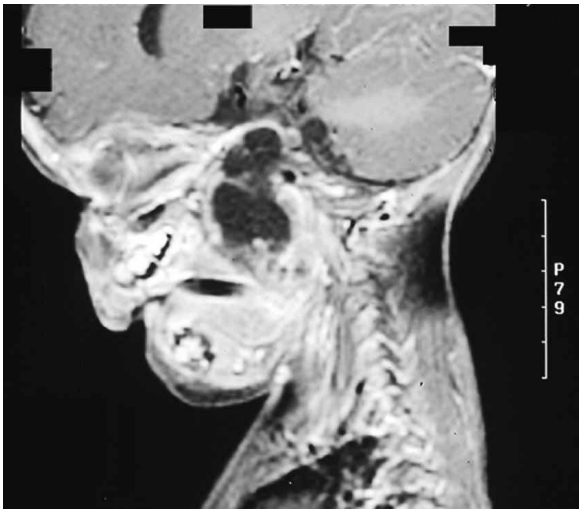

Figure 10 CT of case 3 showing a teratoma of the skull base with an intracranial extension.

alveolar nerve renders a favorable approach to the medial cranial base. Based on our experiences, however, we prefer the *horizontal osteotomy above the mandibular foramen* with additional temporal osteotomy of the zygomatic and exarticulation of the joint. This approach offers an excellent surgical perspective and preserves the blood supply of the mandible (the vascularization of the cranial mandibular segment through the vessels of the inserting muscle). This feature makes this approach even more beneficial, particularly in early childhood.

All three of our children with tumors involving the skull base underwent surgery via a lateral transmandibular approach. The same surgical techniques were used in all patients. Two girls have been followed for years. They are still free of disease and neurological deficits, but both have a growth impairment to a different extent and for different reasons. One girl had undergone radiation before surgery, which led to general retardation of growth. The other girl developed microsomia of the mandible.

Given the severity of their diagnosis, the patients' outcomes were good and their deficits were acceptable. For tumor surgery, the lateral transmandibular approach has been successful in our experience and meets all relevant requirements for skull base surgery in children.

REFERENCES

1. Sisson GA. Cancer of the maxillary sinus; clinical classification and management. Ann Otol Rhinol Laryngol 1963; 72:1050
2. Sollmann WP. Vermeidung von Kieferklemme, Facialisparese und kosmetischen Störungen durch modifizierten pterionalen Zugang zur Schädelbasis. In: Zehm S, ed. Der retromaxilläre Raum. Stuttgart: Thieme-Verlag, 1970
3. Attenborough NR. Maxillectomy via a temporal approach. J Laryngol Otol 1980;94:149–162
4. Obwegeser HL. Temporal approach to the TMJ, the orbit and the retromaxillary-infracranial region. Head Neck Surg 1985;7:185–199
5. Denecke HJ. Der infratemporale Zugangsweg zur Orbita und zur Fossa pterygoidea. In: Schwenzer N, Pfeifer G, eds. Fortschr Kief und Gesichtschir Bd XIV. Stuttgart: Thieme-Verlag; 1970:241–242
6. Teo C, Dornhoffer J, Hanna E, Bower C. Application of skull base techniques to pediatric neurosurgery. Childs Nerv Syst 1999;15:103–109
7. Fujitsu K, Kuwabara T. Zygomatic approach for lesions in the interpenduncular cistern. J Neurosurg 1985;62:340–343
8. Honeybul S, Neil-Dwyer G, Lang D, Evans BT. The transzygomatic approach: a long-term clinical review. Acta Neurochir (Wien) 1995;136:111–116
9. Neil-Dwyer G, Sharr M, Haskell R, Currie D, Hosseini M. Zygomaticotemporal approach to the cranii and basilar artery. Neurosurgery 1988;23:20–22
10. Al-Mefty O, Fox JL. Superolateral orbital exposure and reconstruction. Surg Neurol 1985;23:609–613
11. Fisch U, Pillsbury HC. Infratemporal fossa approach to lesions in the temporal bone and base of the skull. Arch Otolaryngol 1979;105:99–108
12. Sekhar LN, Sen CN, Jho HD, Janecka IP. Surgical treatment of intracavernous neoplasm: a four-year experience. Neurosurgery 1989;24:18–30
13. Biller HF, Shuger JM, Krepsi YP. A new technique for wide-field exposure of the base of the skull. Arch Otolaryngol 1981;107:698–702
14. Krespi YP, Sisson GA. Transmandibular exposure of the skull base. Am J Surg 1984;148:534–538
15. Wood BG, Sadar ES, Levine HL, Dohn DF, Tucker HM. Surgical problems of the base of the skull. Arch Otolaryngol 1980;106:1–5
16. Arita N, Mori S, Sano M, et al. Surgical treatment of tumours in the anterior skull base using the transbasal approach. Neurosurgery 1989;24:379–384

17. Derome PJ. The transbasal approach for tumors invading the base of the skull. In: Schmidek HH, Sweet WH, eds. Operative Neurosurgical Techniques. Indications, Methods and Results. New York: Grune Stratton; 1982:357–379
18. Richtersmeier WJ, Briggs RJ, Koch WM, et al. Complications and early outcome of anterior craniofacial resection. Arch Otolaryngol Head Neck Surg 1992;118:913–917

Commentary

The authors review their surgical technique for and experience with tumors involving the cranial base in children to maximize exposure, to minimize the effect on facial and skull growth, and to preserve the motor and sensory functions of the mandible and masseter muscles. The authors operated on three children via a modified lateral transmandibular approach. Although this technique is not completely novel, its use in such cases is particularly appropriate.

Randall W. Porter, M.D.[1]

Skull Base, volume 13, number 2, 2003. [1]Interdisciplinary Skull Base Section, Division of Neurological Surgery, Barrow Neurological Institute, Phoenix, Arizona. Copyright © 2003 by Thieme Medical Publishers, Inc., 333 Seventh Avenue, New York, NY 10001, USA. Tel: +1(212) 584-4662. 1531-5010,p;2003,13,02,092,092,ftx,en;sbs00328x.